



ORIGINAL ARTICLE

Effect of caffeine on superficial retinal vasculature of the macula in high myopes using optical coherence tomography angiography – A pilot study

Victoria KM Law, Andrew KC Lam*

Centre for Myopia Research, School of Optometry, The Hong Kong Polytechnic University, Hong Kong SAR, China

Received 18 January 2021; accepted 18 June 2021

Available online 28 May 2022



KEYWORDS

Optical coherence tomography angiography;
Myopia;
Caffeine;
Vessel length density;
Perfusion area;
Density

Abstract

Purpose: To monitor effect of caffeine on vasculature of the inner retina of high myopes

Methods: This was a crossover, self-control, randomized trial. Healthy young high myopes were recruited to take 200 mg of caffeine capsule and placebo capsule, randomly assigned in two visits separated by at least one week. Superficial retinal vasculature in terms of vessel length density (VD) and perfusion area density (PD) was captured and monitored using a spectral domain optical coherence tomography angiography (OCTA) machine. After baseline measurements, blood pressure (BP), intraocular pressure (IOP), and subfoveal choroidal thickness (ChT) were also monitored at 30-min intervals till 3 h.

Results: Eighteen subjects (6 male, 24.3 ± 3.1 years) completed the study. After taking the caffeine capsule, there was a significant increase in BP ($p < 0.01$), and reduction in ChT ($p < 0.01$), with no change in IOP ($p = 0.36$). VD demonstrated a trend of reduction at the central 1-mm circle, and 1–3 mm annulus ($p < 0.01$) following the ETDRS grid. Reduction trend of PD appeared at the central 1-mm circle, 1–3 mm annulus, and the entire 3-mm circle ($p < 0.01$). Compared with baseline, VD and PD reductions were significant 180 min after taking the caffeine capsule at the central 1-mm circle, but the reduction was small (VD: by 1mm^{-1} ; PD: by 1%). Changes in other regions were not significant.

Conclusions: The current study found significant reduction in VD and PD after taking 200 mg of caffeine capsule. Such a small amount of alteration may be clinically irrelevant.

© 2021 Spanish General Council of Optometry. Published by Elsevier España, S.L.U. This is an open access article under the CC BY-NC-ND license (<http://creativecommons.org/licenses/by-nc-nd/4.0/>).

Introduction

Caffeine is an adenosine antagonist present in coffee and other beverages. It has an impact on several ocular indices, including ocular blood flow,¹ retinal vessel diameter,² and

* Corresponding author at: Centre for Myopia Research, School of Optometry, The Hong Kong Polytechnic University, Hong Kong SAR, China HKG.

E-mail address: andrew.kc.lam@polyu.edu.hk (A.K. Lam).

ocular accommodation.³ Its effect on intraocular pressure (IOP) has been widely studied. Consumption of caffeine caused an acute increase in IOP in glaucoma patients, but there was no significant effect in healthy individuals.⁴ This finding informed eye care practitioners to remind glaucoma patients not to consume caffeine prior to IOP measurement.

The choroid is responsible for the vascular supply of the outer retina, including photoreceptors at the macula. Previous studies using enhanced depth imaging (EDI) from optical coherence tomography (OCT) revealed thinning of the choroid at the fovea after caffeine intake. Vural et al.⁵ reported a reduction in choroidal thickness after taking one cup of Turkish coffee (with 57 mg caffeine). The choroid was thinnest two hours after intake and returned back to baseline four hours later. Altinkaynak et al.⁶ found a similar thinning and rebound pattern occurred after taking a 200 mg caffeine capsule. Other studies confirmed that caffeine intake could reduce choroidal thickness for a period of 2 to 4 h.^{7,8}

OCT angiography (OCTA) is an advanced non-invasive ophthalmic imaging modality. It can capture microvasculature structures of both the inner and outer retina and the choroid without the use of fluorescent dye, as used in fluorescein angiography.^{9,10} High resolution OCTA can aid detection of proliferative eye problems, including myopic choroidal neovascularization,¹¹ diabetic retinal neovascularization,¹² and microaneurysms.¹³ Fan et al.¹⁴ applied OCTA and found that high myopes had reduced macular vessel length density, making them more susceptible to pathological changes. Other investigators have observed reduced retinal vasculature in high myopes.^{15–18} A recent study evaluated the effect of caffeine intake on retinal vessel length density utilizing OCTA.¹⁹ Both the superficial and deep retinal vasculature was found reduced. It was a placebo-controlled study involving two groups of subjects, and both eyes were included in their analysis.

High myopia is frequently associated with retinal vascular alterations, such as narrower retinal vessels or increased vessel resistance.^{20,21} OCTA has been used to show reduced retinal vasculature of high myopes.^{14–18} Further reduction due to consumption of caffeine, if any, could have negative impact to physiology of the macula. It is worth of testing the effects of caffeine intake in high myopes. The current study used a placebo-controlled balanced crossover study to monitor effects of caffeine on the vasculature of the inner retina of healthy high myopes.

Methods

Subjects

Healthy high myopes were recruited mainly at The Hong Kong Polytechnic University campus. Inclusion criteria were aged between 20 and 29 years, spherical equivalent refraction (sphere plus half cylindrical component) of more than −6.00D, and non-smokers. Subjects were required to refrain from taking caffeine containing beverages for 24 h prior to visiting the campus Optometry Clinic. Exclusion criteria were subjects diagnosed with any ocular or systemic diseases. Written informed consent was obtained before the ophthalmic examination. All procedures adhered to the tenets of the Declaration of Helsinki for research involving

human subjects. The University Institutional Review Board approved this study (HSEARS20170613002).

An initial visit was arranged and baseline measurements obtained, including blood pressure, body mass index (BMI), ocular biometry (IOL Master, Carl Zeiss Meditec, Jena, Germany), non-contact tonometry and optical pachymetry (NT-530P, Nidek Co., Ltd., Gamagori, Japan), and Goldmann applanation tonometry (GAT). Choroidal thickness was measured using a spectral domain OCT 2 (Spectralis, Heidelberg Engineering, Inc., Heidelberg, Germany), and OCTA using the Cirrus 5000 with AngioPlex (Zeiss Meditec, Inc., Dublin, CA, USA).

It took approximately 30 min to complete the baseline measurements. Subjects were then randomly assigned to take either a 200 mg caffeine capsule (SAN Nutrition, SAN Corp. Oxnard, USA) or a 200IU Vitamin capsule (GNC Natural E 200, Nutra Manufacturing, South Carolina, USA). Subjects were not informed about the ingredients of the capsule. The European Food Safety Authority (EFSA) published Scientific Opinion on the Safety of Caffeine in 2015, advising that caffeine intakes from all sources up to 400 mg per day or a single dose of 200 mg do not raise safety concerns for adults in the general population.²² Ocular parameters were measured 30, 60, 120, and 180 min after taking the capsule. For monitoring ocular changes, one eye was randomly selected and ophthalmic measurements, including axial length, non-contact tonometry (NCT), OCT, and OCTA were performed. GAT was measured again only at the end of the study due to the invasive nature of applanation tonometry. Blood pressure was monitored in all four follow-up measurement points.

After a washout period, at least one week, subjects returned and repeated all the procedures by taking other capsule not taken previously. All the measurements in the two visits were conducted between 9am and 1pm to avoid diurnal variation of ocular parameters.²³

OCT and OCTA measurements

For OCT, corneal curvature was entered into the Spectralis system to avoid potential magnification errors. This device utilized a light source with a peak wavelength of 870 nm and a scanning speed of 40,000 A-scan/sec to provide cross-sectional retinal and choroidal images with axial resolution of 3.9 μm and transverse resolution of 14 μm . The acquisition setting included 31 B-scans at 240 μm intervals covering a 30°×25° area centred at the macula. The built-in TruTrack Active Eye Tracking software (Heidelberg Engineering GmbH) was turned on. Each B-scan included an average of 30 images. The high resolution mode was used, and the EDI mode was turned on. The first acquired image was set as reference and all the following images at different time points were captured according to this reference map to ensure the same position was being scanned.

Subfoveal choroidal thickness was manually measured on another day by an experienced observer masked to the measurement condition. Choroidal thickness was measured from the outer portion of the hyper-reflective line corresponding to the retinal pigment epithelium to the inner surface of the sclera. All measurements were performed in 1:1 μm viewing mode²⁴ and 2X magnification was used during measurement.

For OCTA, a 3 × 3 mm macular area was scanned using the angiography mode from the Cirrus system. Signal

strength was at least 7 with no glare or motion artefact in the image¹³. Retinal vessels at the superficial retinal layer (from internal limiting membrane to the inner plexiform layer) were delineated using the AngioPlex software provided by the manufacturer. OCTA metrics including vessel length density (total length of perfused vasculature per unit area in the region of measurement), and perfusion area density (total area of perfused vasculature per unit area in the region of measurement) were provided by the AngioPlex software (version 10) using the ETDRS format. The ETDRS grid divided the 3 × 3 mm macular area into a central 1-mm circle, and a parafoveal 1–3 mm annulus. The 1–3 mm annulus could be further divided into the nasal, temporal, superior and inferior quadrants. Liu et al.²⁵ applied OCTA and found regional variation of vessel density from axial elongation. The foveal avascular zone (FAZ) area was not considered in this study because the proprietary software could not generate repeatable results.²⁶ Furthermore, Karti et al.¹⁹ did not find a significant change in FAZ one hour after caffeine consumption in healthy subjects.

Statistical analysis

Prior to data collection, the minimum sample size required was estimated based on changes in subfoveal choroidal thickness after caffeine consumption,⁶ with an alpha of 0.05 and power of 0.80. A sample size of 16 subjects was projected using G*Power 3.1 software.

We used Generalized Estimating Equations (GEE) to compare intake of caffeine and placebo (Visit) and points of measurement (Time) for each dependent variable. Visit and Time were set as within-subject variables. GEE is powerful to analyse both normal and non-normal repeatedly measured outcome data. Whenever significant difference at 5% for Time or interaction (Visit × Time) was found, pairwise comparisons (with Bonferroni adjustment) were conducted to compare which measurement points had significant difference with baseline. All tests were performed with SPSS Statistics version 26 (IBM SPSS Statistics, IBM Corporation).

Results

Eighteen subjects were recruited, 6 male and 12 female. Their mean age was 24.3 years (SD 3.1). The average spherical equivalent was -8.05 ± 1.71 D (-6.00 to -11.75 D) in the examined eyes. Analyses included 11 right eyes and 7 left eyes.

Table 1 shows BMI, blood pressure, NCT and GAT IOP, axial length, and subfoveal choroidal thickness results. There was no significant difference in BMI at the two visits (Wilcoxon test, $p = 0.17$). Blood pressure had significant interaction ($p < 0.01$). Pairwise comparisons found significant increase in systolic and diastolic blood pressure when taking caffeine. Although a significant interaction was found in NCT IOP ($p < 0.01$), no measurement points had IOP significantly different from baseline. The GAT IOP and axial length were similar throughout the study ($p > 0.05$). Subfoveal choroidal thickness demonstrated a significant effect with Time ($p < 0.01$) and interaction ($p < 0.01$). It showed a trend of reduction when taking caffeine. However, pairwise comparisons did not find any measurement points with significant difference as compared with baseline.

Vessel length density at the central 1-mm, and 1–3 mm annulus showed significant effect with Time ($p < 0.01$). Only VD at the central 1-mm was significantly reduced compared with baseline after 180 min of caffeine intake. Although a trend of reduced VD at the 1–3 mm annulus was apparent, no pairwise comparisons with baseline could reach statistical significance (Table 2). Fig. 1 shows VD at four quadrants in the 1–3 mm annulus. No significant variation with Time or interaction was found from taking either caffeine or placebo capsules (all $p > 0.05$).

Perfusion area density results in each visit are shown in Table 3. There was significant effect with Time at the central 1 mm, 1–3 mm annulus, and the 3-mm full circle ($p < 0.01$). Pairwise comparisons revealed a significantly lower PD at the central 1-mm circle after 180 min of caffeine intake. Fig. 2 shows PD at four quadrants in the 1–3 mm annulus. No significant variation with Time or interaction was found from taking either caffeine or placebo capsules (all $p > 0.05$).

Discussion

To our knowledge, the present study is the first to evaluate the effect of caffeine on retinal vasculature of the macula in high myopes using OCTA. Apparently 200 mg caffeine consumption did not change superficial retinal vasculature very much. Caffeine consumption causes IOP elevation in patients with glaucoma or ocular hypertension.^{27,28} Although this elevation may not be clinically significant,^{29,30} glaucoma patients and glaucoma suspects are reminded not to consume caffeine before follow-up eye examination. Recent studies using a higher dose of caffeine intake revealed IOP rise in healthy adults.^{31,32} Nakano et al.³³ reported that habitual coffee consumption was associated with a slightly lower IOP in healthy subjects. Kim et al.³⁴ did not find causal effect of coffee drinking on IOP. They further concluded that effect of habitual caffeine consumption depended on genetic predisposition.

We could not identify any measurement points with IOP significantly different from baseline. This is important because acute IOP rise could result in reduced retinal vasculature. Ma et al.³⁵ found reduced vessel density at both the macula and optic nerve head during IOP spike after laser peripheral iridotomies. Wang et al.³⁶ had similar findings. The reduction of vessel density was more significant in radial peripapillary capillary than that of the entire retina when IOP rise was moderate, from 5 to 10 mmHg. Zhang et al.³⁷ did not find significant change in vessel density using dark room prone provocative test to induce IOP rise. It might be due to IOP rise not great enough to induce changes in retinal vasculature.³⁵ Our subjects had similar IOP level throughout the study. Any changes in retinal vasculature should not be due to IOP variation.

Terao et al.² analysed retinal vessel diameter from fundus photography and found constriction of retinal vessels one hour after consuming 200 mg caffeine capsule. Retinal vasculature can be evaluated non-invasively using OCTA. Our placebo-controlled balanced crossover study revealed some effects of 200 mg caffeine on superficial retinal vessel length density/perfusion area density in healthy high myopes. Although there was a trend of reduced vessel length

Table 1 BMI, Blood pressure, IOP, axial length, and choroidal thickness throughout the study (Mean \pm SD, or median (interquartile range)).

	Caffeine visit	Placebo visit
BMI (kg/m^2)	20.1 (4.3)	20.6 (4.1)
Wilcoxon test	$p =$	0.17
Blood pressure (mmHg)		
Baseline	Sys: 101.4 ± 9.0 ; Dia: 61.8 ± 5.8	Sys: 101.9 ± 7.7 ; Dia: 61.8 ± 8.1
30–min	Sys: 105.1 ± 8.6 ; Dia: 66.1 ± 7.7	Sys: 99.7 ± 7.7 ; Dia: 61.6 ± 6.6
60–min	Sys: $106.8 \pm 8.6^*$; Dia: $66.8 \pm 7.9^*$	Sys: 101.3 ± 8.0 ; Dia: 62.2 ± 6.3
120–min	Sys: $106.1 \pm 7.7^*$; Dia: 65.8 ± 9.1	Sys: 99.7 ± 8.3 ; Dia: 62.3 ± 5.8
180–min	Sys: 104.6 ± 8.8 ; Dia: 66.3 ± 8.7	Sys: 101.4 ± 8.9 ; Dia: 62.8 ± 7.3
GEE	Sys: Time, $p = 0.04$; Dia: Time, $p < 0.01$; Visit \times Time, $p < 0.01$	Visit \times Time, $p < 0.01$
NCT (mmHg)		
Baseline	15.1 ± 2.4	15.3 ± 2.2
30–min	15.9 ± 2.3	$15.9 (2.7)$
60–min	15.8 ± 2.5	15.2 ± 2.2
120–min	15.7 ± 2.5	$15.7 (3.8)$
180–min	15.7 ± 2.4	14.9 ± 1.9
GEE	Time, $p = 0.56$; Visit \times Time: $p < 0.01$	
GAT (mmHg)		
Baseline	15.4 ± 2.7	15.2 ± 2.4
180–min	15.7 ± 2.4	14.8 ± 2.3
GEE	Time, $p = 0.74$; Visit \times Time: $p = 0.08$	
Axial length (mm)		
Baseline	26.78 ± 0.97	26.78 ± 0.97
30–min	26.78 ± 0.96	26.78 ± 0.96
60–min	26.77 ± 0.97	26.72 ± 1.04
120–min	26.78 ± 0.97	26.78 ± 0.98
180–min	26.79 ± 0.97	26.78 ± 0.97
GEE	Time, $p = 0.77$; Visit \times Time: $p = 0.50$	
Choroidal thickness (μm)		
Baseline	216.6 ± 43.4	212.9 ± 49.0
30–min	219.9 ± 43.5	215.2 ± 49.6
60–min	217.8 ± 44.5	213.6 ± 47.3
120–min	215.9 ± 46.8	211.3 ± 45.2
180–min	212.7 ± 44.9	215.0 ± 47.0
GEE	Time, $p < 0.01$; Visit \times Time: $p < 0.01$	

BMI: body mass index.

Sys: systolic pressure.

Dia: diastolic pressure.

NCT: non–contact tonometry.

GAT: Goldmann applanation tonometry.

GEE: generalized estimating equation.

* significant difference compared with baseline.

density (Table 2) and perfusion area density (Table 3), compared with baseline, only the central 1–mm circle had significant reductions 3 h after caffeine consumption. When macular regions were segregated into four quadrants, all quadrants had similar vessel length and perfusion area densities compared with baseline. Karti et al.¹⁹ found significant reduction in vessel length density one hour after caffeine intake, which involved all four quadrants of the macula. Liu et al.²⁵ found that inferior nasal sector was less susceptible from axial elongation. They hypothesized that it could be related to larger blood flow area in the nasal region.³⁸

It is not surprising to find a trend of reduced retinal blood vessel area (perfusion area density) following caffeine

consumption. Caffeine exerts its antagonist effect at adenosine A2A receptors³⁹ leading to vasoconstriction.⁴⁰ Changes in superficial retinal vasculature could be due to vasoconstriction. Such decreasing trend was not obvious from taking placebo. However, the reduced vasculature was minimal (vessel length density: reduced by 1mm^{-1} , Table 2; perfusion area density: reduced by 1%, Table 3) 3 h after caffeine consumption. This may be due to limited sensitivity of OCTA to detect the small physiological changes in capillaries related to caffeine intake, which could differ from pathological changes, such as those observed in diabetic retinopathy,^{41,42} high myopic choroidal neovascularization,¹¹ or age–related macular degeneration.^{43,44}

Table 2 Vessel length density throughout the study (Mean \pm SD, or median (interquartile range)).

	Caffeine visit	Placebo visit
Centre 1-mm (mm^{-1})		
Baseline	12.23 \pm 2.65	12.21 \pm 2.80
30-min	11.72 \pm 2.86	11.79 \pm 2.83
60-min	11.65 \pm 2.67	11.58 \pm 2.77
120-min	11.65 \pm 2.50	11.83 \pm 2.71
180-min	11.26 \pm 2.92*	11.78 \pm 2.87
GEE	Time, $p < 0.01$; Visit \times Time: $p = 0.19$	
1–3 mm annulus (mm^{-1})		
Baseline	22.35 \pm 0.67	22.40 (0.53)
30-min	22.18 \pm 1.15	22.14 \pm 0.91
60-min	22.12 \pm 1.10	22.20 \pm 0.75
120-min	21.99 \pm 1.14	21.88 \pm 0.97
180-min	21.64 \pm 1.29	22.09 \pm 0.87
GEE	Time, $p < 0.01$; Visit \times Time: $p = 0.35$	
3-mm full circle (mm^{-1})		
Baseline	21.22 \pm 0.69	21.35 (0.55)
30-min	21.00 \pm 1.15	20.99 \pm 0.89
60-min	20.95 \pm 1.09	21.02 \pm 0.75
120-min	20.92 \pm 1.04	20.74 \pm 0.92
180-min	20.80 (1.28)	20.96 \pm 0.84
GEE	Time, $p = 0.20$; Visit \times Time: $p = 0.17$	

GEE: generalized estimating equation.

* significant difference compared with baseline.

Jung et al.⁴⁵ reported that amount of astigmatism could influence OCTA vessel length density and perfusion area density at different quadrants. It could be due to optical blur across different meridians because current OCTA systems incorporate only spherical lens to compensate refractive errors. However, our subjects did not have much astigmatism. The mean astigmatism was -1.00D (SD0.64D).

Even though caffeine causes vessel constriction, it requires vessel diameter to be reduced to an extent quantifiable using perfusion area density or to an extent at which the capillaries are no longer detectable (vessel length density). OCTA uses different technologies to detect flow of red blood cells against static retinal tissues in order to reconstruct the retinal vasculature.⁹ In the current study, microvasculature of the superficial retina was captured using an optical micro-angiography (OMAG) algorithm from the Cirrus AngioPlex. The OMAG algorithm appeared to perform better than other OCTA algorithms, such as split-spectrum amplitude decorrelation angiography algorithm (SSADA) or OCT angiography ratio analysis (OCTARA).⁴⁶ The OMAG algorithm has fewer motion artefacts than the SSADA.^{47,48}

Although OCTA is now commonly used in ophthalmic practice, this technology is limited by severe artefacts, including shadow, defocus, and movement artefacts during acquisition.⁴⁹ Averaging multiple OCTA acquisitions could enhance image quality^{50,51} and be more sensitive in detecting differences,⁵² especially when the scan size is large (such as 6×6 mm) with low resolution in pixel/mm.⁵³ Previous studies have documented the advantage of image averaging in examining retinal vein occlusion⁵⁴ and diabetic retinopathy.⁵⁵ Only one high quality OCTA image was captured in the current study, which could be due to the instrument being incapable of detecting small changes.

Another explanation for the small change in retinal vasculature could be related to the amount of caffeine used. Our subjects took a 200 mg caffeine capsule which was commonly used in previous studies.^{2,6,7,56} Recent studies about the effect of caffeine on IOP or accommodation adopted 4 mg/kg.^{31,32,57,58} Other studies used 5 mg/kg^{59,60} or even 7 mg/kg.⁶¹ Based on the weight of our subjects, the dose of caffeine intake was between 2.5 to 4.7 mg/kg. This amount could be considered low. Caffeine intake based on body

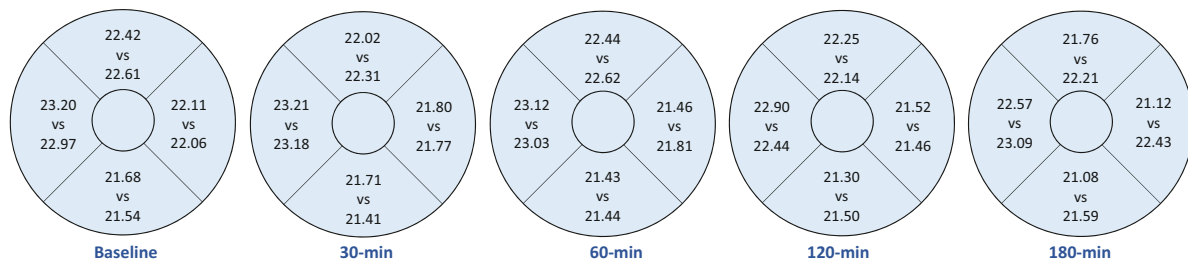


Fig. 1 Results are converted to left-eye configuration. Mean vessel length density (mm^{-1}) of the superior (top), temporal (right), inferior (bottom) and nasal (left) quadrants at different time points. Upper figures: caffeine visit; Lower figures: placebo visit.

Table 3 Perfusion area density throughout the study (Mean \pm SD, or median (interquartile range)).

	Caffeine visit	Placebo visit
Centre 1–mm (%)		
Baseline	18.8 (7.4)	20.2 \pm 4.6
30–min	19.3 \pm 4.7	19.5 \pm 4.9
60–min	19.3 \pm 4.5	19.3 \pm 4.4
120–min	19.1 \pm 4.0	19.1 \pm 4.5
180–min	18.4 \pm 4.9*	19.4 \pm 4.5
GEE	Time, $p < 0.01$; Visit \times Time: $p = 0.12$	
1–3 mm annulus (%)		
Baseline	39.2 \pm 1.2	39.0 \pm 1.2
30–min	38.7 \pm 2.0	38.7 \pm 1.7
60–min	38.6 \pm 1.8	38.7 \pm 1.5
120–min	38.3 \pm 1.8	38.2 \pm 1.6
180–min	38.5 (2.5)	38.6 \pm 1.5
GEE	Time, $p < 0.01$; Visit \times Time: $p = 0.44$	
3–mm full circle (%)		
Baseline	37.7 (2.4)	36.9 \pm 1.2
30–min	36.5 \pm 1.9	36.6 \pm 1.7
60–min	36.4 \pm 1.7	36.6 \pm 1.2
120–min	36.1 \pm 1.7	36.1 \pm 1.6
180–min	36.4 (1.9)	36.5 \pm 1.4
GEE	Time, $p < 0.01$; Visit \times Time: $p = 0.62$	

GEE: generalized estimating equation.

* significant difference compared with baseline.

weight should be used in future studies. We did not record menstrual cycle phases of female subjects. However, Kamimori et al.⁶² found that menstrual cycle did not alter pharmacokinetic of caffeine. We believe that gender should not be a determining factor in the results.

Some limitations were identified in the current study. The analyses were restricted to the superficial retinal vasculature due to the available OCTA metric provided by the proprietary software. Other research groups used customized algorithms to derive middle and deep capillary plexuses.⁶³ Another limitation was not differentiating low and high caffeine consumers. Vera et al.³¹ found that caffeine induced greater IOP change in low-caffeine consumers. Therefore, the ocular effect could be subject to caffeine tolerance. We did not exclude regular coffee drinkers who might also have greater caffeine tolerance. We monitored subjects for 3 h only. Future studies should monitor caffeine effects for a longer period. Effect of caffeine on subfoveal choroidal thickness could last for 4 h and it took 6 h for it to return to baseline level.^{5,6} The caffeine intake used in the current study was relatively small based on subjects' body weights. Finally, the sample size was small, with only 6 male and

12 female, and limited to healthy young high myopes. Effect of caffeine in other refractive groups and also patients with ocular pathologies warrants further studies.

Llanas et al.⁶⁴ highlighted the importance of considering ocular magnification from axial length in OCTA. Axial length of the subjects' eyes ranged from 25.2 to 29.0 mm. Actual vessel length density could be 5% to 20% smaller than the reported values.⁶⁵ However, our study included within-subject comparison and effects between taking caffeine and placebo were still valid.

To conclude, consuming 200 mg caffeine in high myopes reduced subfoveal choroidal thickness and constricted retinal vasculature of the superficial capillary plexus. There was a trend of reduced vessel length density and perfusion area density, which, although small, lasted for a few hours.

Statement of Ethics

Written informed consent was obtained before any ophthalmic examination.

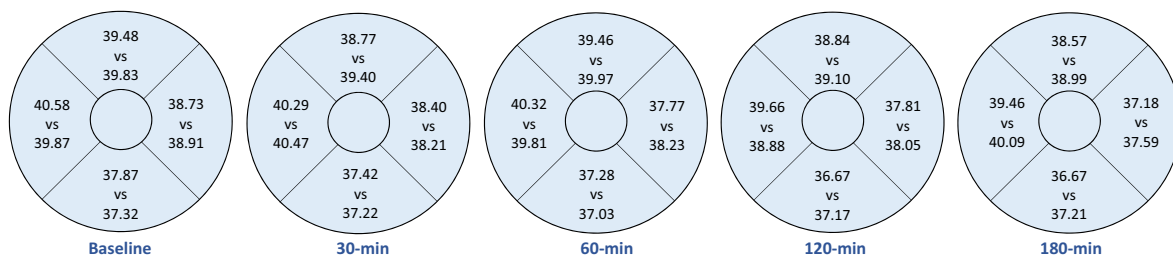


Fig. 2 Results are converted to left–eye configuration. Mean perfusion area density (%) of the superior (top), temporal (right), inferior (bottom) and nasal (left) quadrants at different time points. Upper figures: caffeine visit; Lower figures: placebo visit.

Funding support

None.

Authors contribution

V.K.M.L. and A.K.C.L. designed the study; V.K.M.L. collected the data; V.K.M.L. and A.K.C.L. analysed and interpreted the data; A.K.C.L. wrote the manuscript; V.K.M.L. and A.K.C.L. involved in final approval of the article.

Declaration of Competing of Interest

The authors have no conflicts of interest to declare.

Acknowledgements

We thank Dr Bing Zuo and Mr Horae Wong in choroidal thickness measurement. We thank Dr Maureen Boost to provide English editing service. Part of the results of this study was presented at the 2019 American Academy of Optometry Annual Meeting

References

- Okuno T, Sugiyama T, Tominaga M, Kojima S, Ikeda T. Effects of caffeine on microcirculation of the human ocular fundus. *Jpn J Ophthalmol.* 2002;46(2):170–176. [https://doi.org/10.1016/s0021-5155\(01\)00498-1](https://doi.org/10.1016/s0021-5155(01)00498-1). [published Online First: Epub Date].
- Teraï N, Spoerl E, Pillunat LE, Stodtmeister R. The effect of caffeine on retinal vessel diameter in young healthy subjects. *Acta Ophthalmol.* 2012;90(7):e524–e528. <https://doi.org/10.1111/j.1755-3768.2012.02486.x>. [published Online First: Epub Date].
- Redondo B, Vera J, Molina R, Luque-Casado A, Jiménez R. Caffeine alters the dynamics of ocular accommodation depending on the habitual caffeine intake. *Exp Eye Res.* 2019;185: 107663. <https://doi.org/10.1016/j.exer.2019.05.003>. [published Online First: Epub Date].
- Li M, Wang M, Guo W, Wang J, Sun X. The effect of caffeine on intraocular pressure: a systematic review and meta-analysis. Graefe's archive for clinical and experimental ophthalmology = Albrecht von Graefes Archiv fur klinische und experimentelle. *Ophthalmologie.* 2011;249(3):435–442. <https://doi.org/10.1007/s00417-010-1455-1>. [published Online First: Epub Date].
- Vural AD, Kara N, Sayin N, Pirhan D, Ersan HB. Choroidal thickness changes after a single administration of coffee in healthy subjects. *Retina.* 2014;34(6):1223–1228. <https://doi.org/10.1097/iae.000000000000043>. [published Online First: Epub Date].
- Altinkaynak H, Ceylan E, Kartal B, Keleş S, Ekinçi M, Olcaysu OO. Measurement of choroidal thickness following caffeine intake in healthy subjects. *Curr Eye Res.* 2016;41(5):708–714. <https://doi.org/10.3109/02713683.2015.1020168>. [published Online First: Epub Date].
- Zengin MO, Cinar E, Karahan E, Tuncer I, Kucukerdonmez C. The effect of caffeine on choroidal thickness in young healthy subjects. *Cutan Ocul Toxicol.* 2015;34(2):112–116. <https://doi.org/10.3109/15569527.2014.912659>. [published Online First: Epub Date].
- Yeung SC, You Y, Howe KL, Yan P. Choroidal thickness in patients with cardiovascular disease: a review. *Surv Ophthalmol.* 2020;65(4):473–486. <https://doi.org/10.1016/j.survophthal.2019.12.007>. [published Online First: Epub Date].
- Gao SS, Jia Y, Zhang M, et al. Optical coherence tomography angiography. *Invest Ophthalmol Vis Sci.* 2016;57(9). <https://doi.org/10.1167/iov.15-19043>. Oct27-36[published Online First: Epub Date].
- Spaide RF, Fujimoto JG, Waheed NK, Sadda SR, Staurengi G. Optical coherence tomography angiography. *Prog Retin Eye Res.* 2018;64:1–55. <https://doi.org/10.1016/j.preteyeres.2017.11.003>. [published Online First: Epub Date].
- Bruyère E, Miere A, Cohen SY, et al. Neovascularization secondary to high myopia imaged by optical coherence tomography angiography. *Retina.* 2017;37(11):2095–2101. <https://doi.org/10.1097/iae.0000000000001456>. [published Online First: Epub Date].
- Hirano T, Hoshiyama K, Hirabayashi K, et al. Vitreoretinal interface slab in OCT angiography for detecting diabetic retinal neovascularization. *Ophthalmol Retina.* 2020;4(6):588–594. <https://doi.org/10.1016/j.oret.2020.01.004>. [published Online First: Epub Date].
- Parrulli S, Corvi F, Cozzi M, Monteduro D, Zicarelli F, Staurengi G. Microaneurysms visualisation using five different optical coherence tomography angiography devices compared to fluorescein angiography. *Br J Ophthalmol.* 2020. <https://doi.org/10.1136/bjophthalmol-2020-316817>. [published Online First: Epub Date].
- Fan H, Chen HY, Ma HJ, et al. Reduced macular vascular density in myopic eyes. *Chin Med J.* 2017;130(4):445–451. <https://doi.org/10.4103/0366-6999.199844>. [published Online First: Epub Date].
- Al-Sheikh M, Phasukkijwatana N, Dolz-Marco R, et al. Quantitative OCT Angiography of the Retinal Microvasculature and the Choriocapillaris in Myopic Eyes. *Invest Ophthalmol Vis Sci.* 2017;58(4):2063–2069. <https://doi.org/10.1167/iov.16-21289>. [published Online First: Epub Date].
- Hassan M, Sadiq MA, Halim MS, et al. Evaluation of macular and peripapillary vessel flow density in eyes with no known pathology using optical coherence tomography angiography. *Int J Retina Vitreous.* 2017;3:27. <https://doi.org/10.1186/s40942-017-0080-0>. [published Online First: Epub Date].
- Mo J, Duan A, Chan S, Wang X, Wei W. Vascular flow density in pathological myopia: an optical coherence tomography angiography study. *BMJ Open.* 2017;7(2):e013571. <https://doi.org/10.1136/bmjopen-2016-013571>. [published Online First: Epub Date].
- Milani P, Montesano G, Rossetti L, Bergamini F, Pece A. Vessel density, retinal thickness, and choriocapillaris vascular flow in myopic eyes on OCT angiography. Graefe's archive for clinical and experimental ophthalmology = Albrecht von Graefes Archiv fur klinische und experimentelle. *Ophthalmologie.* 2018;256(8):1419–1427. <https://doi.org/10.1007/s00417-018-4012-y>. [published Online First: Epub Date].
- Karti O, Zengin MO, Kerici SG, Ayhan Z, Kusbeci T. Acute effect of caffeine on macular microcirculation in healthy subjects: an optical coherence tomography angiography study. *Retina (Philadelphia, Pa).* 2019;39(5):964–971. <https://doi.org/10.1097/iae.0000000000002058>. [published Online First: Epub Date].
- Lim LS, Cheung CY, Lin X, Mitchell P, Wong TY, Mei-Saw S. Influence of refractive error and axial length on retinal vessel geometric characteristics. *Invest Ophthalmol Vis Sci.* 2011;52(2):669–678. <https://doi.org/10.1167/iov.10-6184>. [published Online First: Epub Date].
- Benavente-Pérez A, Hosking SL, Logan NS, Broadway DC. Ocular blood flow measurements in healthy human myopic eyes. Graefe's archive for clinical and experimental

- ophthalmology = Albrecht von Graefes Archiv für klinische und experimentelle. *Ophthalmologie*. 2010;248(11):1587–1594. <https://doi.org/10.1007/s00417-010-1407-9>. [published Online First: Epub Date].
22. EFSA Panel on Dietetic Products N, Allergies. Scientific Opinion on the safety of caffeine. *EFSA J*. 2015;13(5):4102. <https://doi.org/10.2903/j.efsa.2015.4102>. [published Online First: Epub Date].
 23. Read SA, Collins MJ, Iskander DR. Diurnal variation of axial length, intraocular pressure, and anterior eye biometrics. *Invest Ophthalmol Vis Sci*. 2008;49(7):2911–2918. <https://doi.org/10.1167/iovs.08-1833>. [published Online First: Epub Date].
 24. Kim JH, Kang SW, Ha HS, Kim SJ, Kim JR. Overestimation of subfoveal choroidal thickness by measurement based on horizontally compressed optical coherence tomography images. Graefe's archive for clinical and experimental ophthalmology = Albrecht von Graefes Archiv für klinische und experimentelle. *Ophthalmologie*. 2013;251(4):1091–1096. <https://doi.org/10.1007/s00417-012-2147-9>. [published Online First: Epub Date].
 25. Liu M, Wang P, Hu X, Zhu C, Yuan Y, Ke B. Myopia-related stepwise and quadrant retinal microvascular alteration and its correlation with axial length. *Eye*. 2020. <https://doi.org/10.1038/s41433-020-01225-y>. [published Online First: Epub Date].
 26. Lin A, Fang D, Li C, Cheung CY, Chen H. Reliability of foveal avascular zone metrics automatically measured by Cirrus optical coherence tomography angiography in healthy subjects. *Int Ophthalmol*. 2020;40(3):763–773. <https://doi.org/10.1007/s10792-019-01238-x>. [published Online First: Epub Date].
 27. Avisar R, Avisar E, Weinberger D. Effect of coffee consumption on intraocular pressure. *Ann Pharmacother*. 2002;36(6):992–995. <https://doi.org/10.1345/aph.1A279>. [published Online First: Epub Date].
 28. Chandrasekaran S, Rohtchina E, Mitchell P. Effects of caffeine on intraocular pressure: the Blue Mountains Eye Study. *J Glaucoma*. 2005;14(6):504–507. <https://doi.org/10.1097/01.jgg.0000184832.08783.be>. [published Online First: Epub Date].
 29. Higginbotham EJ, Kilimanjaro HA, Wilensky JT, Batenhorst RL, Hermann D. The effect of caffeine on intraocular pressure in glaucoma patients. *Ophthalmology*. 1989;96(5):624–626. [https://doi.org/10.1016/s0161-6420\(89\)32852-1](https://doi.org/10.1016/s0161-6420(89)32852-1). [published Online First: Epub Date].
 30. Jiwani AZ, Rhee DJ, Brauner SC, et al. Effects of caffeinated coffee consumption on intraocular pressure, ocular perfusion pressure, and ocular pulse amplitude: a randomized controlled trial. *Eye*. 2012;26(8):1122–1130. <https://doi.org/10.1038/eye.2012.113>. [published Online First: Epub Date].
 31. Vera J, Redondo B, Molina R, Bermúdez J, Jiménez R. Effects of caffeine on intraocular pressure are subject to tolerance: a comparative study between low and high caffeine consumers. *Psychopharmacology*. 2019;236(2):811–819. <https://doi.org/10.1007/s00213-018-5114-2>. [published Online First: Epub Date].
 32. Redondo B, Vera J, Molina R, Jiménez R. Short-term effects of caffeine intake on anterior chamber angle and intraocular pressure in low caffeine consumers. Graefe's archive for clinical and experimental ophthalmology = Albrecht von Graefes Archiv für klinische und experimentelle. *Ophthalmologie*. 2020;258(3):613–619. <https://doi.org/10.1007/s00417-019-04556-z>. [published Online First: Epub Date].
 33. Nakano E, Miyake M, Hosoda Y, et al. Relationship between intraocular pressure and coffee consumption in a Japanese population without glaucoma: the Nagahama study. *Ophthalmol Glaucoma*. 2020. <https://doi.org/10.1016/j.ogla.2020.09.019>. [published Online First: Epub Date].
 34. Kim J, Aschard H, Kang JH, et al. Intraocular pressure, glaucoma and dietary caffeine consumption: a gene-diet interaction study from the UK Biobank. *Ophthalmology*. 2020. <https://doi.org/10.1016/j.ophtha.2020.12.009>. [published Online First: Epub Date].
 35. Ma ZW, Qiu WH, Zhou DN, Yang WH, Pan XF, Chen H. Changes in vessel density of the patients with narrow anterior chamber after an acute intraocular pressure elevation observed by OCT angiography. *BMC Ophthalmol*. 2019;19(1):132. <https://doi.org/10.1186/s12886-019-1146-6>. [published Online First: Epub Date].
 36. Wang X, Chen J, Kong X, Sun X. Immediate Changes in Peripapillary Retinal Vasculature after Intraocular Pressure Elevation -an Optical Coherence Tomography Angiography Study. *Curr Eye Res*. 2020;45(6):749–756. <https://doi.org/10.1080/02713683.2019.1695843>. [published Online First: Epub Date].
 37. Zhang Q, Jonas JB, Wang Q, et al. Optical coherence tomography angiography vessel density changes after acute intraocular pressure elevation. *Sci Rep*. 2018;8(1):6024. <https://doi.org/10.1038/s41598-018-24520-x>. [published Online First: Epub Date].
 38. Zhou M, Lu B, Zhang P, Zhao J, Wang Q, Sun X. Determination of topographic variations in inner retinal blood flow areas in young chinese subjects using optical coherence tomography angiography. *Curr Eye Res*. 2017;42(11):1491–1496. <https://doi.org/10.1080/02713683.2016.1266662>. [published Online First: Epub Date].
 39. Fredholm BB, Bättig K, Holmén J, Nehlig A, Zvartau EE. Actions of caffeine in the brain with special reference to factors that contribute to its widespread use. *Pharmacol Rev*. 1999;51(1):83–133.
 40. Polska E, Ehrlich P, Luksch A, Fuchsjäger-Mayrl G, Schmetterer L. Effects of adenosine on intraocular pressure, optic nerve head blood flow, and choroidal blood flow in healthy humans. *Invest Ophthalmol Vis Sci*. 2003;44(7):3110–3114. <https://doi.org/10.1167/iovs.02-1133>. [published Online First: Epub Date].
 41. Dimitrova G, Chihara E, Takahashi H, Amano H, Okazaki K. Quantitative retinal optical coherence tomography angiography in patients with diabetes without diabetic retinopathy. *Invest Ophthalmol Vis Sci*. 2017;58(1):190–196. <https://doi.org/10.1167/iovs.16-20531>. [published Online First: Epub Date].
 42. Sun Z, Tang F, Wong R, et al. OCT angiography metrics predict progression of diabetic retinopathy and development of diabetic macular edema: a prospective study. *Ophthalmology*. 2019;126(12):1675–1684. <https://doi.org/10.1016/j.ophtha.2019.06.016>. [published Online First: Epub Date].
 43. Lee SC, Tran S, Amin A, et al. Retinal vessel density in exudative and nonexudative age-related macular degeneration on optical coherence tomography angiography. *Am J Ophthalmol*. 2020;212:7–16. <https://doi.org/10.1016/j.ajo.2019.11.031>. [published Online First: Epub Date].
 44. Shin YI, Kim JM, Lee MW, Jo YJ, Kim JY. Characteristics of the foveal microvasculature in asian patients with dry age-related macular degeneration: an optical coherence tomography angiography study. *Ophthalmologica*. 2020;243(2):145–153. <https://doi.org/10.1159/000503295>. [published Online First: Epub Date].
 45. Jung JJ, Soh YQ, Sha P, Yu S, Durbin MK, Hoang QV. Effects of induced astigmatism on spectral domain-OCT angiography quantitative metrics. *Am J Ophthalmol*. 2020;219:49–58. <https://doi.org/10.1016/j.ajo.2020.07.005>. [published Online First: Epub Date].
 46. Munk MR, Giannakaki-Zimmermann H, Berger L, et al. OCT-angiography: a qualitative and quantitative comparison of 4 OCT-A devices. *PLoS ONE*. 2017;12(5):e0177059. <https://doi.org/10.1371/journal.pone.0177059>. [published Online First: Epub Date].
 47. De Vitis LA, Benatti L, Tomasso L, et al. Comparison of the performance of two different spectral-domain optical coherence tomography angiography devices in clinical practice.

- Ophthalmic Res.* 2016;56(3):155–162. <https://doi.org/10.1159/000447094>. [published Online First: Epub Date].
48. Chung CS, Nesper PL, Park JJ, Fawzi AA. Comparison of zeiss cirrus and optovue RTVue OCT angiography systems: a quantitative and qualitative approach examining the three capillary networks in diabetic retinopathy. *Ophthalmic Surg Lasers Imaging Retina.* 2018;49(11):e198–e205. <https://doi.org/10.3928/23258160-20181101-18>. [published Online First: Epub Date].
 49. Holmen IC, Konda MS, Pak JW, et al. Prevalence and severity of artifacts in optical coherence tomographic angiograms. *JAMA Ophthalmol.* 2019;138(2):119–126. <https://doi.org/10.1001/jamaophthalmol.2019.4971>. [published Online First: Epub Date].
 50. Uji A, Balasubramanian S, Lei J, Baghdasaryan E, Al-Sheikh M, Sadda SR. Impact of multiple en face image averaging on quantitative assessment from optical coherence tomography angiography images. *Ophthalmology.* 2017;124(7):944–952. <https://doi.org/10.1016/j.ophtha.2017.02.006>. [published Online First: Epub Date].
 51. Mikhail M, Jiang S, Hahn P, Orlin A, Rao RC, Choudhry N. OCTA: a practical method of image averaging using adobe photoshop software. *Ophthalmic Surg Lasers Imaging Retina.* 2019;50(12):802–807. <https://doi.org/10.3928/23258160-20191119-09>. [published Online First: Epub Date].
 52. Khan HM, Gentle A, Armitage JA, To CH, Lam AKC. Multiple scan averaging to yield accurate quantitative analysis of optical coherence tomography angiograms. *Sci Rep.* 2020;10(1):6194. <https://doi.org/10.1038/s41598-020-62956-2>. [published Online First: Epub Date].
 53. Uji A, Balasubramanian S, Lei J, et al. Multiple enface image averaging for enhanced optical coherence tomography angiography imaging. *Acta Ophthalmol (Copenh).* 2018;96(7). <https://doi.org/10.1111/aos.13740>. e820-e27[published Online First: Epub Date].
 54. Jung JJ, Yu DJG, Zeng A, et al. Correlation of quantitative measurements with diabetic disease severity using multiple en face OCT angiography image averaging. *Ophthalmol Retina.* 2020. <https://doi.org/10.1016/j.oret.2020.04.029>. [published Online First: Epub Date].
 55. Jung JJ, Chen MH, Shi Y, et al. Correlation of en face optical coherence tomography averaging versus single-image quantitative measurements with retinal vein occlusion visual outcomes. *Retina.* 2020;40(4):786–794. <https://doi.org/10.1097/iae.0000000000002453>. [published Online First: Epub Date].
 56. Dervişoğlu MS, Totan Y, Yüce A, Kulak AE. Acute effects of caffeine on choroidal thickness and ocular pulse amplitude. *Cutan Ocul Toxicol.* 2016;35(4):281–286. <https://doi.org/10.3109/15569527.2015.1104330>. [published Online First: Epub Date].
 57. Vera J, Redondo B, Bardón A, Pérez-Castilla A, García-Ramos A, Jiménez R. Effects of caffeine consumption on intraocular pressure during low-intensity endurance exercise: a placebo-controlled, double-blind, balanced crossover study. *Clin Experiment Ophthalmol.* 2020;48(5):602–609. <https://doi.org/10.1111/ceo.13755>. [published Online First: Epub Date].
 58. Redondo B, Vera J, Carreño-Rodríguez C, Molina-Romero R, Jiménez R. Acute effects of caffeine on dynamic accommodative response and pupil size: a placebo-controlled, double-blind, balanced crossover study. *Curr Eye Res.* 2020;1–8. <https://doi.org/10.1080/02713683.2020.1725060>. [published Online First: Epub Date].
 59. Osei KA, Ovenseri-Ogbomo G, Kyei S, Ntodie M. The effect of caffeine on tear secretion. *Optometry Vis Sci.* 2014;91(2):171–177. <https://doi.org/10.1097/oxp.000000000000129>. [published Online First: Epub Date].
 60. Connell CJ, Thompson B, Kuhn G, Claffey MP, Duncan S, Gant N. Fatigue related impairments in oculomotor control are prevented by caffeine. *Sci Rep.* 2016;6:26614. <https://doi.org/10.1038/srep26614>. [published Online First: Epub Date].
 61. Arita R, Yanagi Y, Honda N, et al. Caffeine increases tear volume depending on polymorphisms within the adenosine A2a receptor gene and cytochrome P450 1A2. *Ophthalmology.* 2012;119(5):972–978. <https://doi.org/10.1016/j.ophtha.2011.11.033>. [published Online First: Epub Date].
 62. Kamimori GH, Joubert A, Otterstetter R, Santaromana M, Eddington ND. The effect of the menstrual cycle on the pharmacokinetics of caffeine in normal, healthy eumenorrheic females. *Eur J Clin Pharmacol.* 1999;55(6):445–449. <https://doi.org/10.1007/s002280050654>. [published Online First: Epub Date].
 63. Zhu Q, Xing X, Zhu M, et al. A new approach for the segmentation of three distinct retinal capillary plexuses using optical coherence tomography angiography. *Transl Vis Sci Technol.* 2019;8(3):57. <https://doi.org/10.1167/tvst.8.3.57>. [published Online First: Epub Date].
 64. Llanas S, Linderman RE, Chen FK, Carroll J. Assessing the use of incorrectly scaled optical coherence tomography angiography images in peer-reviewed studies: a systematic review. *JAMA Ophthalmol.* 2019. <https://doi.org/10.1001/jamaophthalmol.2019.4821>. [published Online First: Epub Date].
 65. Sampson DM, Gong P, An D, et al. Axial length variation impacts on superficial retinal vessel density and foveal avascular zone area measurements using optical coherence tomography angiography. *Invest Ophthalmol Vis Sci.* 2017;58(7):3065–3072. <https://doi.org/10.1167/iov.17-21551>. [published Online First: Epub Date].