



# Bone Grafting Can Promote the Prognosis of Displaced Femoral Neck Fractures: A Follow-up of the Clinical Significance of Bone Defects

Xiaozhong Zhu, MD, Wei Wang, MD\*, Zhiyuan Wang, MD<sup>†</sup>, Yi Zhu, MD, Guangyi Li, MD, Jiong Mei, MD

Department of Orthopaedic Surgery, Shanghai Sixth People's Hospital Affiliated to Shanghai Jiao Tong University School of Medicine, Shanghai,

\*Department of Biomedical Engineering, The Hong Kong Polytechnic University, Hong Kong,

<sup>†</sup>Department of Orthopedics, Tongji Hospital, School of Medicine, Tongji University, Shanghai, China

**Background:** Femoral neck fractures (FNFs) comprise a large proportion of osteoporotic fractures in Asia. However, the full range of prognostic variables that affect prognosis remains unclear. Here, we aimed to determine whether the severity of bone defects at the fracture site and other variables impact the prognosis of displaced FNFs.

**Methods:** We evaluated the incidence of FNF internal fixation failures at regular intervals after surgery in data collected retrospectively. Digital Imaging and Communications in Medicine (DICOM) magnetic resonance imaging data of the displaced FNFs of 204 patients (> 20 years old; mean age, 52.3 years; men, 55.4%) who underwent internal fixation were used to construct three-dimensional (3D) virtual models of the femoral neck region. We calculated the position and volume of bone defect (VBD) using our independently developed algorithm and Mimics software. Each participant was followed up for at least 24 months; complications were noted and correlated with VBD and demographic and clinical variables.

**Results:** On the basis of VBD values calculated from virtual reduction models, 57 patients were categorized as having a mild defect, 100 as having a moderate defect, and 47 as having a severe defect. Age ( $p = 0.046$ ) and VBD ( $p < 0.001$ ) were significantly correlated with internal fixation failure. Multivariate analysis revealed that severe bone defects were associated with internal fixation failure (adjusted odds ratio [aOR], 23.073; 95% confidence interval [CI], 2.791–190.732) and complications (aOR, 8.945; 95% CI, 1.829–43.749). In patients with a severe defect, bone grafting was inversely associated with internal fixation failure (aOR, 0.022; 95% CI, 0.002–0.268) and complications (aOR, 0.023; 95% CI, 0.002–0.299).

**Conclusions:** Bone defect severity was associated with internal fixation failure and other complications. For young adults with large VBDs, bone grafting of the defect can reduce the risk of internal fixation failure. These results provide useful new quantitative information for precisely classifying displaced FNFs and guiding subsequent optimal treatments.

**Keywords:** Femoral neck fracture, Internal fixation, Bone defect, Virtual reduction

Received January 20, 2023; Revised February 14, 2023;

Accepted February 16, 2023

Correspondence to: Jiong Mei, MD

Department of Orthopaedic Surgery, Shanghai Sixth People's Hospital Affiliated to Shanghai Jiao Tong University School of Medicine, 600 Yishan Rd, Shanghai 200233, China

Tel: +86-13901870631

E-mail: meijiong@sjtu.edu.cn

Xiaozhong Zhu and Wei Wang contributed equally to this study.

Femoral neck fractures (FNFs) have a high incidence in the general population<sup>1,2)</sup> and are reported frequently in most trauma centers around the world. It is estimated that by the middle of the century, 50% or more of all osteoporosis-related fractures will occur in Asia,<sup>3,4)</sup> largely because of the disproportionate increase in aging populations in Asian countries in coming years.<sup>4)</sup> FNFs are a significant healthcare problem worldwide because of their enormous impact on healthcare insurance costs and a high probability of extended disability and/or institutionalization.<sup>5)</sup> Inter-

nal fixation of the fracture is the gold-standard treatment for younger adult patients, while arthroplasty is mainly performed in older patients. Treatment selection depends on fracture-related conditions, a patient's demographic profile, personal preferences, and a surgeon's training and skill level.<sup>6-10</sup> The mechanical strength of the femoral neck is determined primarily by bone density, bone geometry, and thickness of the cortical bone.<sup>11</sup> Bone defects in FNFs are strongly associated with the prognosis after internal fixation. Prognostic factors for FNFs include insufficient fracture reduction (especially, varus deformity), difficulty in carrying out fracture reduction, and comminution of the posterior neck cortex.

Comminution of the posterior neck cortex is the main reason for problematic fracture reduction and internal fixation failure, with the failure caused by insufficient fracture reduction.<sup>12-14</sup> Advanced age, difficulty in achieving fracture reduction, and poor preoperative conditions are also associated with FNF fixation failure.<sup>15-18</sup> For example, the presence of fracture varus reduction or difficulty in achieving the reduction increases the risk of fixation failure by 4.3 times.<sup>18</sup> One prognostic variable that has received little research attention, however, is the severity of the bone defect. Specifically, it is unknown whether the severity of a bone defect is associated with the prognosis of FNFs. This study assessed the impact of bone defects on the internal fixation failure of displaced FNFs.

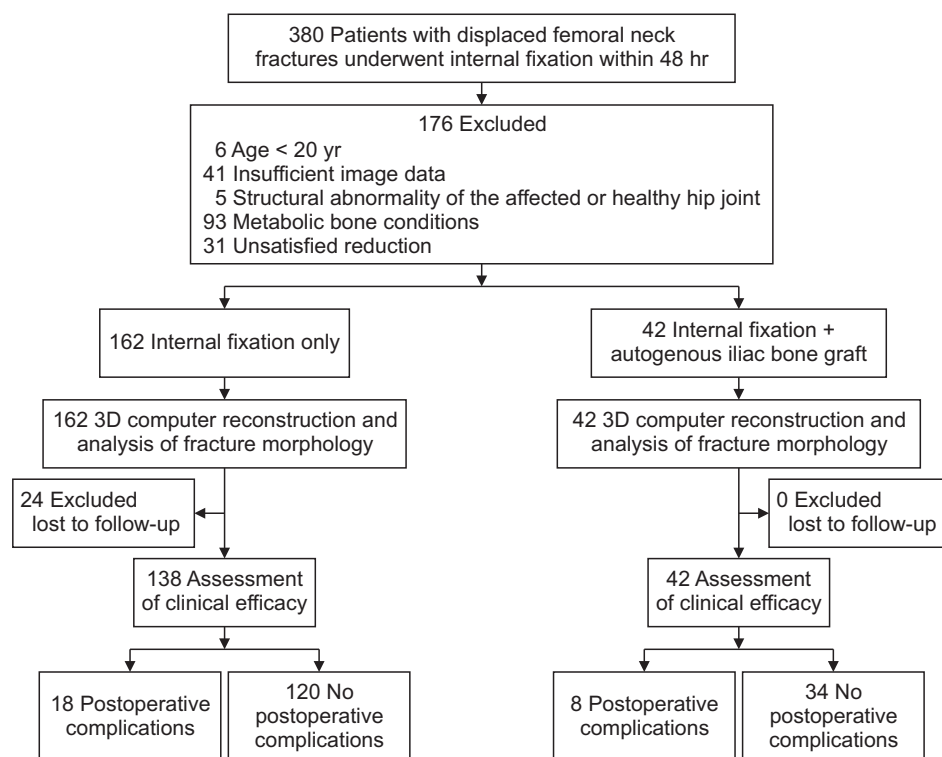
## METHODS

This study was performed in line with the principles of the Declaration of Helsinki. Approval was granted by the Ethics Committees of Shanghai Sixth People's Hospital affiliated to Shanghai Jiao Tong University School of Medicine (No. 2020-KY-026 (K)). Informed consent was obtained from all individual participants included in the study. The authors affirm that human research participants provided informed consent for publication of the images.

### Clinical Data

#### Study design and sample

This retrospective study enrolled patients from two level 1 trauma centers. These patients were treated between January 2014 and December 2018. Inclusion criteria were (1) those > 20 years old and having a history of trauma, (2) those diagnosed with a displaced FNF, Garden III-IV, OTA/AO fracture classified as 31B1.3 and 31B2 (1-3) that had undergone internal fixation, (3) those who had available preoperative X-ray images of anterior-posterior (AP) and lateral femoral neck and computed tomography (CT) scan in Digital Imaging and Communications in Medicine (DICOM) format of bilateral proximal femurs, (4) follow-up longer than 24 months, (5) anatomical reduction, and (6) internal fixation completed within 48 hours after injury. Exclusion criteria were (1) those ≤ 20



**Fig. 1.** Flowchart for patient inclusion. 3D: three-dimensional.

years old, (2) those who had Garden I-II or non-displaced FNF, (3) X-ray and CT scans showing the abnormal ipsilateral or contralateral hip structure, femoral neck malformation, or pathological FNF, (4) metabolic bone conditions including diabetes mellitus, heavy smoker, current alcohol misuse, current steroid use, end-stage renal disease, and osteoporosis, and (5) unsatisfied reduction.

A total of 204 patients met the inclusion criteria, including 113 men (55.4%) and 91 women (44.6%). Their mean age was 52.3 years (range, 21 to 75 years). All cases were subjected to three-dimensional (3D) computer reconstruction and analysis of fracture morphology. Twenty-four cases (11.8%) did not complete the follow-up, leaving 180 cases for the assessment of clinical efficacy (Fig. 1).

#### Internal fixation surgery

Of the included patients, 66 cases underwent closed reduction and 138 underwent open reduction. Of the open reduction cases, 36 were cases that previously had undergone closed reduction that had failed and 102 had undergone open reduction directly. A bone graft was performed in 42 cases having severe bone defects at the fracture site; the iliac cortex together with cancellous bone adjacent to it was harvested for the graft. For internal fixation, either 3 or 4 cannulated screws (6.5 mm or 7.3 mm in length) or dynamic hip screws (DHSs) were used.

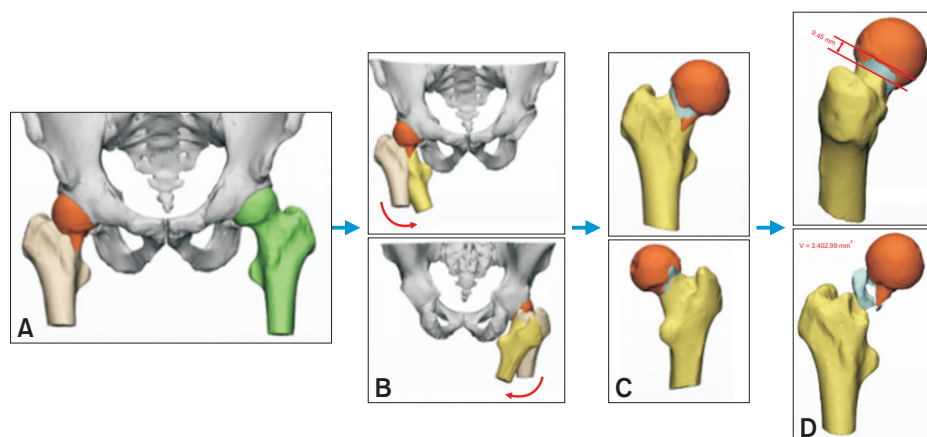
Anatomic reduction was defined as less than 2 mm step-off at the fracture site or less than 5° in varus/valgus alignment compared to the corresponding site on the con-

tralateral side on immediate postoperative radiographs.<sup>19)</sup> In cases undergoing fixation with cannulated screws, screws were inserted close to the femoral neck cortex. In the remaining cases, DHSs were positioned close to the longitudinal axis of the femoral neck. Thin-slice CT scans together with AP view and lateral view X-rays were examined on the first postoperative day to evaluate reduction quality and were used as references for comparison of subsequent images taken at follow-up visits.

The average surgical intervention time was 58 minutes (range, 40–100 minutes) for internal fixation only and 126 minutes (range, 90–150 minutes) for internal fixation combined with autogenous iliac bone graft. Discovery of newly emerging hip symptoms (e.g., pain, soft-tissue irritation, or other significant discomforts) in treated patients was recorded and examined with additional X-ray and CT scans.

#### Outcome measures

The primary outcome variable was postoperative complications, such as superficial incisional infection, deep vein thrombosis, or internal fixation failure. Internal fixation was considered to be a failure if a change in the relative position of the implant within the distal femoral neck was detected on imaging scans; i.e., a displacement seen in the AP view and/or lateral view of the femoral neck compared with immediate postoperative X-ray and CT images. However, patients tracked in the failure group did not include controllable shortening of the femoral neck (within 10



**Fig. 2.** Brief schematic overview of the virtual reduction and related measurements calculated from three-dimensional (3D) reconstructions. The computed tomography data were imported into Mimics software and 3D reconstructions of the proximal and distal ends of the fractures were created. Then, the parts were exported to 3-matic in STL format. (A) The healthy femur was mirrored to the affected side using the mirror tool. (B) The affected femur was aligned and repositioned onto the mirrored femur using N-point registration and global registration tools. (C) Anterior and posterior views of the reduced model. Boolean operations were then used to obtain the model of the bone defect. (D) The volume of bone defect and the maximum defect height were calculated.

mm) due to the compression of bone fragments with parallel screws.

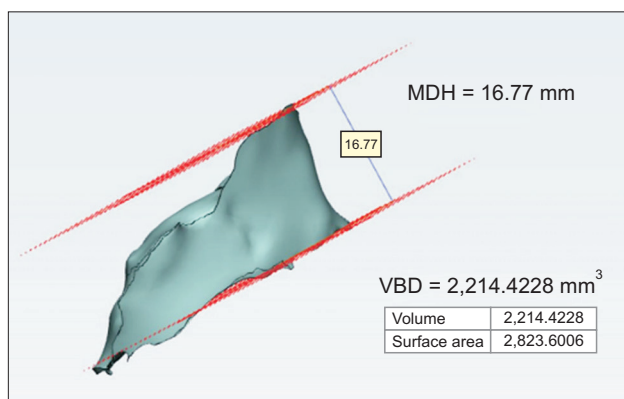
### Data Collection and Analysis

DICOM data were obtained by using a Toshiba Aquilion ONE 320-slice SPIRAL CT scanner (Toshiba Inc., Tokyo, Japan). The scanning parameters were 80 kV, 200 mA, slice thickness of 0.625 mm, and tube rotation of 0.35 sec. The data were imported into Materialise Mimics software (Materialise NV, Leuven, Belgium) to create individual 3D models of the pelvis, affected femoral head, affected femoral shaft, and contralateral femur, which were then imported into Materialise 3-matic (Materialise NV) in STL format. Next, the computerized processing we established previously was applied to measure various bone-defect variables (Fig. 2). These variables were the volume of bone defect (VBD) and the maximum defect height (MDH) on virtual reduction (Fig. 3).

A cross-section of the femoral neck 3D model at the fracture end was divided into four parts by vertical and horizontal virtual lines in the model. Two planes were created through the vertical and horizontal lines to divide the whole femoral neck into four quadrants. The four quadrants—anterosuperior, anteroinferior, posterosuperior, and posteroinferior—were denoted as quadrant I (QI), quadrant II (QII), quadrant III (QIII), and quadrant IV (QIV), respectively (Fig. 4). The number of quadrants involved (NQI) in the fracture was recorded as well as the main distribution area of bone defects (anterior, posterior, superior, or inferior).

### Statistical Analysis

Continuous variables were expressed as mean ( $\pm$  standard deviation) and categorical variables as number (%). Con-



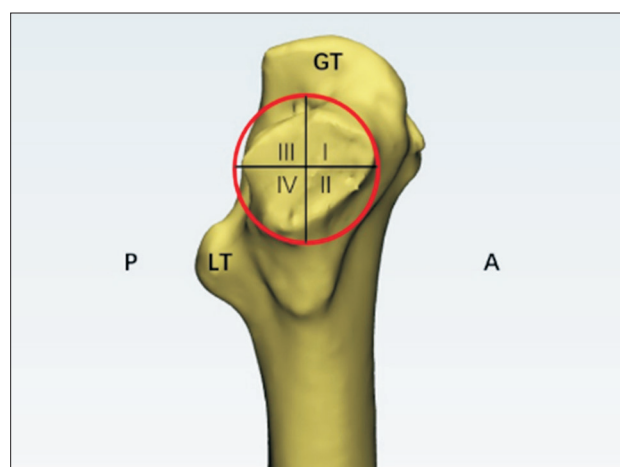
**Fig. 3.** The volume of bone defect (VBD) is displayed in the system once the bone defect model is reconstructed. Two paralleled sketches were created to measure the maximum defect height (MDH).

tinuous data of group variables were evaluated statistically using the Mann-Whitney test or Kruskal-Wallis test, and categorical data were analyzed using Pearson's chi-test or Fisher's exact test. Univariate analyses were used to evaluate associations between variables and outcomes. Variables for which significant differences were found in univariate analyses were included in multivariate logistic regression analyses to identify risk factors for complications. Failures of internal fixation were one of the main complications of interest.

Results were expressed as odds ratios (ORs) with 95% confidence intervals (CIs). Regression analysis of complications excluded patients lost to follow-up ( $n = 24$ ). All statistical assessments were two-tailed and considered statistically significant at  $p < 0.05$ . IBM SPSS statistical software ver. 22 for Windows (IBM Corp., Armonk, NY, USA) was used for all statistical analyses.

## RESULTS

Patients' demographic and clinical characteristics are presented in Table 1. All of our patients with displaced FNFs had femoral neck bone defects that might distribute across any quadrants of the femoral neck (Table 1). Most bone defects occurred in the posterior femoral neck (94.6%). On the basis of the quartile cutoff points, bone defects were categorized as mild ( $VBD \leq 2,710.97 \text{ mm}^3$ ), moderate ( $2,710.97 \text{ mm}^3 < VBD < 5,136.14 \text{ mm}^3$ ), or severe ( $VBD$



**Fig. 4.** Four quadrants of the cross-section of the femoral neck three-dimensional model at the fracture end. Vertical and horizontal lines are drawn through the center of the fracture surface in the virtual model to divide it into four parts for analysis: (1) anterior-superior quadrant (QI), (2) anterior-inferior quadrant (QII), (3) posterior-superior quadrant (QIII), and (4) posterior-inferior quadrant (QIV). GT: greater trochanter, P: posterior, LT: lesser trochanter, A: anterior.

$\geq 5,136.14 \text{ mm}^3$ ); for this grouping, 57 patients (27.9%), 100 patients (49.0%), and 47 patients (23.0%), respectively, had mild, moderate, or severe defects.

The mean  $\pm$  SD MDH was  $14.62 \pm 4.92 \text{ mm}$ . The mean MDH was significantly larger for patients who underwent internal fixation combined with autogenous iliac bone graft compared to patients who underwent internal fixation only ( $17.52 \pm 4.83$  vs.  $13.87 \pm 4.67$ ;  $p < 0.001$ ). Of

the patients who underwent internal fixation, 11 (5.4%) had anterior bone defects (QI + QII), 193 cases (94.6%) had posterior bone defects (QIII + QIV), 114 (55.9%) had superior bone defects (QI + QIII), and 90 patients (44.1%) had inferior bone defects (QII + QIV). A total of 26 patients (12.7%) had surgical complications, and of these, 17 (8.3%) had an internal fixation failure.

Statistical analyses showed that age ( $p = 0.046$ ) and

**Table 1.** Demographic and Clinical Characteristics of Study Population Grouped by ORIF Type

Variable	Total	ORIF		p-value
		ORIF only	ORIF + autogenous iliac bone graft	
Case	204 (55.1)	162 (79.4)	42 (20.6)	-
Age (yr)				0.595 <sup>†</sup>
< 50	63 (30.9)	49 (30.2)	14 (33.3)	
50–59	86 (42.2)	72 (44.4)	14 (33.3)	
60–69	40 (19.6)	30 (18.5)	10 (23.8)	
$\geq 70$	15 (7.4)	11 (6.8)	4 (9.5)	
Sex				0.001 <sup>†</sup>
Male	113 (55.4)	80 (49.4)	33 (78.6)	
Female	91 (44.6)	82 (50.6)	9 (21.4)	
VBD*				< 0.001 <sup>†</sup>
Mild	57 (27.9)	55 (34.0)	2 (4.8)	
Moderate	100 (49.0)	86 (53.1)	14 (33.3)	
Large	47 (23.0)	21 (13.0)	26 (61.9)	
MDH (mm)	$14.62 \pm 4.92$	$13.87 \pm 4.67$	$17.52 \pm 4.83$	< 0.001 <sup>§</sup>
Main distribution area of bone defect				0.036 <sup>†</sup>
Anterior	11 (5.4)	6 (3.7)	5 (11.9)	
Posterior	193 (94.6)	156 (96.3)	37 (88.1)	
Main distribution area of bone defect				0.608 <sup>†</sup>
Superior	114 (55.9)	92 (56.8)	22 (52.4)	
Inferior	90 (44.1)	70 (43.2)	20 (47.6)	
NQI				< 0.001 <sup>†</sup>
$\leq 2$	104 (51.0)	94 (58.0)	10 (23.8)	
$\geq 3$	100 (49.0)	68 (42.0)	32 (76.2)	
ORIF method				0.645 <sup>†</sup>
Cannulated screw	128 (62.75)	102 (63.0)	26 (61.9)	
DHS	41 (20.10)	34 (21.0)	7 (16.7)	
Diamond configuration	35 (17.16)	26 (16.0)	9 (21.4)	

**Table 1.** Continued

Variable	Total	ORIF		p-value
		ORIF only	ORIF + autogenous iliac bone graft	
Complication				0.286 <sup>†</sup>
No	154 (75.50)	120 (74.1)	34 (81.0)	
Yes	26 (12.7)	18 (11.1)	8 (19.0)	
Internal fixation failure	17 (8.3)	14 (8.6)	3 (7.1)	0.098 <sup>†</sup>
Superficial incisional infection	4 (2.0)	2 (1.2)	2 (4.8)	0.398 <sup>‡</sup>
DVT	5 (2.5)	2 (1.2)	3 (7.1)	0.100 <sup>†</sup>

Values are presented as number (%) or mean ± standard deviation.

ORIF: open reduction for internal fixation, VBD: volume of bone defect, MDH: maximum defect height, NQI: number of quadrants involved, DHS: dynamic hip screws, DVT: deep vein thrombosis.

\*Mild, total volume (mm<sup>3</sup>) ≤ 2,710.97; Moderate, 2,710.97 < total volume (mm<sup>3</sup>) < 5,136.14; Large, total volume (mm<sup>3</sup>) ≥ 5,136.14. <sup>†</sup>Kruskal-Wallis test.

<sup>‡</sup>Pearson's chi-square test. <sup>§</sup>One-way analysis of variance. <sup>||</sup>Fisher's exact test.

**Table 2.** Characteristics of ORIF Cases According to Final Status

Variable	ORIF		p-value
	Success	Failure	
Case	187 (91.7)	17 (8.3)	-
Age (yr)			0.046
< 50	60 (32.1)	3 (17.6)	
50–59	80 (42.8)	6 (35.3)	
60–69	36 (19.3)	4 (23.5)	
≥ 70	11 (5.9)	4 (23.5)	
Sex			0.213
Male	101 (54.0)	12 (70.6)	
Female	86 (46.0)	5 (29.4)	
VBD			< 0.001
Mild	56 (29.9)	1 (5.9)	
Moderate	99 (52.9)	1 (5.9)	
Large	32 (17.1)	15 (88.2)	
MDH (mm)	14.44 ± 4.89	16.58 ± 4.98	0.086
Main distribution area of bone defect			0.926
Anterior	10 (5.3)	1 (5.9)	
Posterior	177 (94.7)	16 (94.1)	
Main distribution area of bone defect			0.202
Superior	107 (57.2)	7 (41.2)	
Inferior	80 (42.8)	10 (58.85)	

**Table 2.** Continued

Variable	ORIF		p-value
	Success	Failure	
NQI			0.735
≤ 2	96 (51.3)	8 (47.1)	
≥ 3	91 (48.7)	9 (52.9)	
Autogenous iliac bone graft			0.754
No	148 (79.1)	14 (82.4)	
Yes	39 (20.9)	3 (17.6)	

Values are presented as number (%) or mean ± standard deviation.

ORIF: open reduction for internal fixation, VBD: volume of bone defect, MDH: maximum defect height, NQI: number of quadrants involved.

**Table 3.** Univariate and Multivariate Logistic Regression between Variables and ORIF Status

Variable	OR (95% CI)	aOR (95% CI)
Age (yr)		
< 50	Reference	Reference
50–59	1.500 (0.360–6.241)	1.326 (0.280–6.274)
60–69	2.222 (0.470–10.501)	3.154 (0.532–18.696)
≥ 70	7.273 (1.426–37.087)	3.427 (0.538–21.843)
Sex		
Male	2.044 (0.692–6.031)	NA
Female	Reference	Reference
VBD		
Mild	Reference	Reference
Moderate	0.566 (0.035–9.220)	0.475 (0.029–7.857)
Large	26.250 (3.311–208.092)	23.073 (2.791–190.732)
MDH	1.083 (0.988–1.188)	NA
Main distribution area of bone defect		
Anterior*	Reference	Reference
Posterior <sup>†</sup>	0.904 (0.109–7.519)	NA
Main distribution area of bone defect		
Superior <sup>‡</sup>	Reference	Reference
Inferior <sup>§</sup>	1.911 (0.697–5.238)	NA
NQI		
≤ 2	Reference	Reference
≥ 3	1.187 (0.439–3.209)	NA

**Table 3.** Continued

Variable	OR (95% CI)	aOR (95% CI)
Autogenous iliac bone graft		
No	Reference	Reference
Yes	0.813 (0.223–2.972)	NA

Reference = success of ORIF.

ORIF: open reduction for internal fixation, OR: odds ratio, CI: confidence interval, aOR: adjusted odds ratio, NA: not applicable, VBD: volume of bone defect, MDH: maximum defect height, NQI: number of quadrants involved.

\*Maximum quadrant of bony defect stratified by I + II. <sup>†</sup>Maximum quadrant of bony defect stratified by III + IV. <sup>‡</sup>Maximum quadrant of bony defect stratified by I + III. <sup>§</sup>Maximum quadrant of bony defect stratified by II + IV.

VBD ( $p < 0.001$ ) correlated significantly with internal fixation failure (Table 2). Univariate and multivariate logistic regression analyses showed that severe bone defects had a significantly higher risk of internal fixation failure than mild bone defects (OR, 26.250; 95% CI, 3.311–208.092; adjusted OR [aOR], 23.073; 95% CI, 2.791–190.732) (Table 3).

The results of univariate and multivariate logistic regression analyses of complications and associations with different demographic and clinical variables are shown in Table 4. In 104 patients (51.0%), the NQI was less than 2; and in 100 patients (49.0%), the NQI was greater than 3. Patients over 70 years old had a 4.73-fold higher risk of complications compared with those younger than 50 years old. Patients with severe bone defects also had a higher risk of complications (OR, 10.062; 95% CI, 2.138–47.351; aOR, 8.945; 95% CI, 1.829–43.749) compared to those with mild bone defects. Patients with bone defects primarily within II + IV quadrants of their fracture had a 2.12-fold

**Table 4.** Univariate and Multivariate Logistic Regression between Variables and Complications

Variable	OR (95% CI)	aOR (95% CI)
Age (yr)		
< 50	Reference	Reference
50–59	1.600 (0.456–5.609)	1.347 (0.363–5.003)
60–69	2.600 (0.679–9.955)	2.815 (0.677–11.698)
≥ 70	4.727 (1.023–21.852)	2.567 (0.499–13.214)
Sex		
Male	0.426 (0.158–1.144)	NA
Female	Reference	Reference
VBD		
Mild	Reference	Reference
Moderate	1.725 (0.334–8.901)	1.473 (0.280–7.757)
Large	10.062 (2.138–47.351)	8.945 (1.829–43.749)
MDH	1.046 (0.957–1.142)	NA
Main distribution area of bone defect		
Anterior	Reference	Reference
Posterior	0.604 (0.122–2.997)	NA
Main distribution area of bone defect		
Superior	Reference	Reference
Inferior	2.122 (0.856–5.256)	NA
NQI		
≤ 2	Reference	Reference
≥ 3	1.262 (0.516–3.090)	NA
Autogenous iliac bone graft		
No	Reference	Reference
Yes	0.997 (0.344–2.889)	NA

Reference = no complication.

OR: odds ratio, CI: confidence interval, aOR: adjusted odds ratio, NA: not applicable, VBD: volume of bone defect, MDH: maximum defect height, NQI: number of quadrants involved.

higher risk of complications (95% CI, 0.856–5.256) than those with bone defects primarily within I + III quadrants of their fracture (Table 4).

The relationship between bone grafting and prognosis as a function of VBD is shown in Table 5. Univariate analysis showed that patients who had a large VBD and received bone grafting had a 0.10-fold (95% CI, 0.022–0.430)

increased risk of internal fixation failure. After adjusting for age, the risk of internal fixation failure in these patients was 0.02-fold (95% CI, 0.002–0.268). Univariate analysis showed that patients with severe bone defects who had a large VBD and who received bone grafting had a 0.11-fold (95% CI, 0.024–0.474) increased risk of postoperative complications. After adjusting for age, the risk of postoperative complications for these patients was 0.02-fold (95% CI, 0.002–0.299) (Table 5).

## DISCUSSION

The present study showed that in patients with displaced FNFs, severe bone defects were associated with internal fixation failure and complications. For young patients with a large VBD, our results indicate that the rate of internal fixation failure and the incidence of complications can be reduced by autogenous bone grafting.

Anatomic reduction of the fracture site is the standard for improving the efficacy of internal fixation. Closed reduction is the most frequently used method for treating displaced FNFs. However, surgeons tend to neglect the severity of the bone defect at the fracture site when performing closed reductions. If the condition of bone defects is not assessed adequately, performing treatments like bone grafting may be delayed or not performed at all, resulting in a spatial defect that could impede bone healing and cause subsequent internal fixation attempts to fail.

Research shows that comminution is more likely to occur in displaced FNFs and is correlated with large Pauwels angles.<sup>15,20</sup> Also, patients with displaced FNFs have significantly higher treatment failure rates than those with non-displaced FNFs. Although these studies did not assess bone defect severity *per se*, the high failure rate observed in those studies is likely to be correlated with large bone defects because it is known that larger displacement and Pauwels angles lead to larger VBDs.<sup>15,20</sup> It is noteworthy that the VBDs we obtained from the virtual reduction computer models of our patients' FNFs were sometimes larger or appeared more severe than they appeared in their X-ray images (Figs. 5 and 6). As we demonstrated in the present study, large-volume bone defects increase fracture fixation failure rates.

The present study showed that bone defects observed in FNFs can occur throughout the femoral neck and in different "directions" or angles. In our patient sample of 204 patients, the defects were predominately in the posterior quadrants of the femoral neck. Shortening of the femoral neck after internal fixation is correlated with the bone density of the femoral head and neck at the time



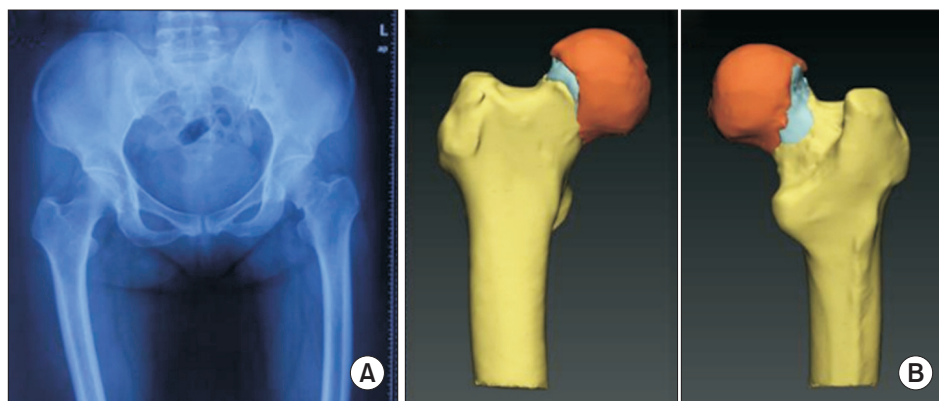
**Table 5.** Associations between Outcomes and Bone Grafts Stratified by Total Volume of Bone Defects

Variable	Model 1		Model 2	
	OR (95% CI)	aOR (95% CI)	OR (95% CI)	aOR (95% CI)
Mild (total volume [mm <sup>3</sup> ] ≤ 2,710.97, n = 57)				
Autogenous iliac bone graft				
No	Reference	Reference	Reference	Reference
Yes	NA*	NA*	NA*	NA*
Moderate (2,710.97 < total volume [mm <sup>3</sup> ] < 5,136.14, n = 100)				
Autogenous iliac bone graft				
No	Reference	Reference	Reference	Reference
Yes	NA*	NA*	2.833 (0.466–17.225)	3.724 (0.537–25.842) <sup>†</sup>
Large (total volume [mm <sup>3</sup> ] ≥ 5,136.14, n = 47)				
Autogenous iliac bone graft				
No	Reference	Reference	Reference	Reference
Yes	0.098 (0.022–0.430)	0.022 (0.002–0.268) <sup>†</sup>	0.107 (0.024–0.474)	0.023 (0.002–0.299) <sup>†</sup>

Model 1: Reference = success of ORIF, Model 2: Reference = no complication.

OR: odds ratio, CI: confidence interval, aOR: adjusted odds ratio, NA: not applicable.

\*Unable to get statistics due to data limitation. <sup>†</sup>Adjusted for age.

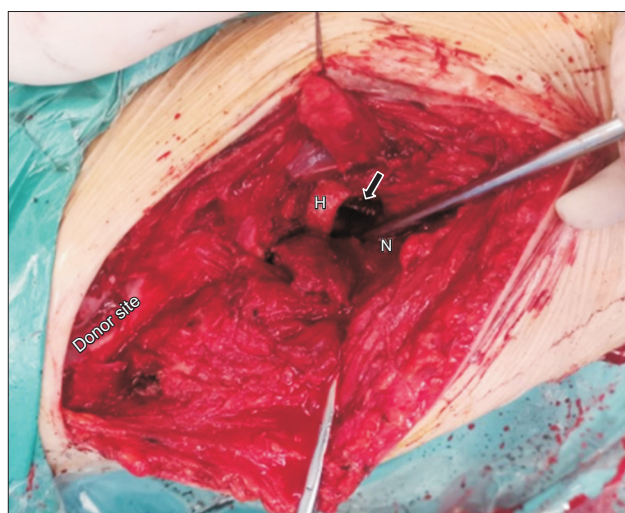


**Fig. 5.** A case of a 51-year-old woman with a femoral neck fracture. (A) The anterior-posterior X-ray view of the femoral neck does not suggest a severe displacement. (B) Virtual reduction in the three-dimensional (3D) model showing the reconstructed bone defect region. In the 3D model, large bone defects became apparent in both the anterior and posterior femoral neck.

of fracture.<sup>21)</sup> We previously found that the main defect region, collapse type, and maximum defect thickness significantly affect the VBD of FNFs, and this partially explains the large individual differences we observed in the VBDs of patients in the present study.

As our present findings revealed, bone defects could also occur anywhere in the femoral neck, although cortical fragmentation and bone defects caused by FNFs mainly affect the posterior part of the femoral neck. In our patient sample, the degree and size of cortical comminution differed, and these differences impacted fracture stability in different ways.

Displacement of an FNF is manifested primarily as a backward tilt of the femoral head and in the femoral neck's forward angle, which results in the compression of cancellous bone or the fragmentation of cortical bone in the posterior part of the femoral neck.<sup>22,23)</sup> Problems resulting from bone fragmentation and defects in the posterior part of FNFs are well documented.<sup>24)</sup> Despite satisfactory reduction and placement of internal fixation devices, posterior FNFs remain displaced postoperatively due to the near vertical angle of the fracture surface and posterior femoral neck cortex fracture.<sup>12,25)</sup> Comminution in posterior parts of the femoral neck is the main reason for the



**Fig. 6.** After anatomic reduction in a 51-year-old female patient, the inserted screw was seen passing through the defect caused by cortical compression. An autogenous iliac bone graft was used to increase fracture stability. Arrow: cannulated screw, H: femoral head, N: femoral neck.

re-displacement in these kinds of FNFs. Fragmentation or compression posteriorly influences the internal fixation of FNFs and affects the prognosis.<sup>26)</sup>

In the present study, we demonstrated that posterior comminutions of the femoral neck appear to be more extensive in virtual reduction models than what can be observed in X-ray images alone. In virtual reduction models, we observed small bone fragments scattered elsewhere in the joint and some cervical cortical bones embedded in the femoral cancellous bone. After fracture reduction and internal fixation, a large gap remained in the femoral neck,<sup>27)</sup> which caused a lack of cortical support. This lack of support significantly reduced internal fixation stability. The anteroposterior position of bone defects affects the stability of FNFs, causing different degrees of instability in the fracture end. Fracture instabilities caused by defects distributed in different directions cannot be treated effectively by using only the internal fixation method. Bone grafting remains the most effective stabilization method, which achieves good results for posterior FNFs.<sup>28-30)</sup>

The present study demonstrated that assessment of bone defects in virtual reduction models of patients' FNFs can reveal details of fractures that can aid treatment decisions and improve the efficacy of the treatment and prognosis. Nonetheless, this study has some limitations as a retrospective study. Retrospective evaluation of clinical data affords only limited inferences about causation and long-term patient follow-up. In addition, as these data

were collected retrospectively, selection bias might exist. Therefore, further prospective studies with a clear definition of the implanted patients are needed to confirm the results of the present study.

In FNFs, the severity of bone defects was associated with the rate of internal fixation failure and complications. In young patients with a large VBD, bone grafting of the defect area can reduce the risk of internal fixation failure and complications. Regardless of the kind of internal fixation used, inevitably, a proportion of patients who undergo internal fixation will experience treatment failure, as seen in this study. Bone defects related to FNFs are one of the main reasons for this failure. Thus, it is crucial for clinicians to assess the location, position, and extent of bone defects and take them into consideration when planning fixation strategies. In patients with FNFs, even when arthroplasty is indicated, the location and extent of the bone defect should be included as part of the assessment of FNFs. Virtual 3D computer models of the femoral head and neck created from routine CT scans can be a useful aid in the assessment of the location, position, and extent of bone defects in FNFs.

## CONFLICT OF INTEREST

No potential conflict of interest relevant to this article was reported.

## ACKNOWLEDGEMENTS

This study was supported by National Natural Science Foundation of China (12172224).

We gratefully acknowledge the assistance of Ming Ni (Department of Orthopaedics, Shanghai Key Laboratory for Prevention and Treatment of Bone and Joint Diseases, Shanghai Institute of Traumatology and Orthopaedics, Ruijin Hospital) in clinical data collecting and statistical analysis. We also thank Chao Jiang (Department of Orthopedics, Tongji Hospital, School of Medicine, Tongji University) for patient follow-up and establishment of 3D models.

## ORCID

Xiaozhong Zhu	<a href="https://orcid.org/0000-0002-1582-9423">https://orcid.org/0000-0002-1582-9423</a>
Wei Wang	<a href="https://orcid.org/0000-0001-8487-444X">https://orcid.org/0000-0001-8487-444X</a>
Zhiyuan Wang	<a href="https://orcid.org/0000-0002-2796-426X">https://orcid.org/0000-0002-2796-426X</a>
Yi Zhu	<a href="https://orcid.org/0000-0002-1538-1876">https://orcid.org/0000-0002-1538-1876</a>
Guangyi Li	<a href="https://orcid.org/0000-0003-4487-4386">https://orcid.org/0000-0003-4487-4386</a>
Jiong Mei	<a href="https://orcid.org/0000-0003-2290-3238">https://orcid.org/0000-0003-2290-3238</a>

## REFERENCES

1. Simonen O. Incidence of femoral neck fractures: senile osteoporosis in Finland in the years 1970-1985. *Calcif Tissue Int.* 1991;49 Suppl:S8-10.
2. Miyamoto RG, Kaplan KM, Levine BR, Egol KA, Zuckerman JD. Surgical management of hip fractures: an evidence-based review of the literature. I: femoral neck fractures. *J Am Acad Orthop Surg.* 2008;16(10):596-607.
3. Dhanwal DK, Dennison EM, Harvey NC, Cooper C. Epidemiology of hip fracture: worldwide geographic variation. *Indian J Orthop.* 2011;45(1):15-22.
4. Cooper C, Campion G, Melton LJ 3rd. Hip fractures in the elderly: a world-wide projection. *Osteoporos Int.* 1992;2(6):285-9.
5. Institute of Medicine (US) Division of Health Promotion and Disease Prevention, Berg RL, Cassells JS. The second fifty years: promoting health and preventing disability. Washington (DC): National Academies Press; 1992.
6. Macaulay W, Pagnotto MR, Iorio R, Mont MA, Saleh KJ. Displaced femoral neck fractures in the elderly: hemiarthroplasty versus total hip arthroplasty. *J Am Acad Orthop Surg.* 2006;14:287-93.
7. Zlowodzki M, Tornetta P 3rd, Haidukewych G, et al. Femoral neck fractures: evidence versus beliefs about predictors of outcome. *Orthopedics.* 2009;32(4):orthosupersite.com/view.asp?rID=38062.
8. Hoskins W, Webb D, Bingham R, Pirpiris M, Griffin XL. Evidence based management of intracapsular neck of femur fractures. *Hip Int.* 2017;27(5):415-24.
9. Onativia IJ, Slullitel PA, Diaz Dilernia F, et al. Outcomes of nondisplaced intracapsular femoral neck fractures with internal screw fixation in elderly patients: a systematic review. *Hip Int.* 2018;28(1):18-28.
10. Yoon YC, Kim J, Cho JW, Cho WT, Kim HJ, Oh JK. Simple guidelines for evaluating intraoperative alignment after the reduction of intertrochanteric fractures. *Asian J Surg.* 2021;44(1):66-71.
11. Augat P, Bliven E, Hackl S. Biomechanics of femoral neck fractures and implications for fixation. *J Orthop Trauma.* 2019;33 Suppl 1:S27-32.
12. Scheck M. Intracapsular fractures of the femoral neck: comminution of the posterior neck cortex as a cause of unstable fixation. *J Bone Joint Surg Am.* 1959;41:1187-200.
13. Asnis SE, Wanek-Sgaglione L. Intracapsular fractures of the femoral neck: results of cannulated screw fixation. *J Bone Joint Surg Am.* 1994;76(12):1793-803.
14. Bray TJ. Femoral neck fracture fixation: clinical decision making. *Clin Orthop Relat Res.* 1997;(339):20-31.
15. Collinge CA, Finlay A, Rodriguez-Buitrago A, et al. Treatment failure in femoral neck fractures in adults less than 50 years of age: analysis of 492 patients repaired at 26 North American Trauma Centers. *J Orthop Trauma.* 2022;36(6):271-9.
16. Griffin J, Anthony TL, Murphy DK, Brennan KL, Brennan ML. What is the impact of age on reoperation rates for femoral neck fractures treated with internal fixation and hemiarthroplasty?: a comparison of hip fracture outcomes in the very elderly population. *J Orthop.* 2016;13(1):33-9.
17. van der List JP, El Saddy S, Vos SJ, Temmerman OP. Role of preoperative posterior tilt on the outcomes of internal fixation of non-displaced femoral neck fractures: a systematic review and meta-analysis. *Injury.* 2021;52(3):316-23.
18. Chua D, Jaglal SB, Schatzker J. Predictors of early failure of fixation in the treatment of displaced subcapital hip fractures. *J Orthop Trauma.* 1998;12(4):230-4.
19. Berkes MB, Little MT, Lazaro LE, Cymerman RM, Helfet DL, Lorich DG. Catastrophic failure after open reduction internal fixation of femoral neck fractures with a novel locking plate implant. *J Orthop Trauma.* 2012;26(10):e170-6.
20. Han Z, Taxi W, Jia H, et al. Multiple cannulated screw fixation of femoral neck fractures with comminution in young- and middle-aged patients. *J Orthop Surg Res.* 2022;17(1):280.
21. Lund EA, Samtani R, Winston M, et al. Association of perioperative computed tomography Hounsfield units and failure of femoral neck fracture fixation. *J Orthop Trauma.* 2020;34(12):632-8.
22. Bigelow HJ. The mechanism of dislocation and fracture of the hip with the reduction of the dislocations by the flexion method. Philadelphia: Lea and Febiger; 1869. 118-38.
23. Frangenheim P. Studien über Schenkelhalsfrakturen und die Vorgänge bei ihrer Heilung. *Deutsche Zeitschrift für Chirurgie.* 1906;83(5):401-55.
24. Linton P. On different types of intracapsular fractures of the femoral neck: surgical investigation of origin, treatment, prognosis and complications in 365 cases. *Acta Chir Scandinav.* 1944;90:1-122.
25. Scheck M. Comminuted fractures of the posterior wall of the neck of the femur. *Clin Orthop Relat Res.* 1967;54:13-28.
26. Caviglia HA, Osorio PQ, Comando D. Classification and diagnosis of intracapsular fractures of the proximal femur. *Clin Orthop Relat Res.* 2002;(399):17-27.

27. Scheck M. The significance of posterior comminution in femoral neck fractures. *Clin Orthop Relat Res.* 1980;(152):138-42.
28. Baksi DP. Internal fixation of ununited femoral neck fractures combined with muscle-pedicle bone grafting. *J Bone Joint Surg Br.* 1986;68(2):239-45.
29. Meyers MH, Harvey JP Jr, Moore TM. Treatment of displaced subcapital and transcervical fractures of the femoral neck by muscle-pedicle-bone graft and internal fixation: a preliminary report on one hundred and fifty cases. *J Bone Joint Surg Am.* 1973;55(2):257-74.
30. Meyers MH, Harvey JP Jr, Moore TM. The muscle pedicle bone graft in the treatment of displaced fractures of the femoral neck: indications, operative technique, and results. *Orthop Clin North Am.* 1974;5(4):779-92.