

Title: Lockdown in Hong Kong promotes myopia progression in school children--case report

Authors

Ka Yan LEUNG^a, BSc (Hons) Optom, MSc in Optometry

Carly Siu Yin LAM^{a,c}, MSc, PhD, MCOptom, FAAO

Sheung Shun NG^a, BSc (Hons) Optom, PhD, FAAO

Dominic Chun Pong CHIM^b, PDip (Optom)

^a Centre for Myopia Research, School of Optometry, The Hong Kong Polytechnic University, Hung Hom, Kowloon, Hong Kong, China.

^b The Optometry (OPT) Centre, RM 918, Hollywood Plaza, 610 Nathan Road, Kowloon, Hong Kong.

^c Centre for Eye and Vision Research, Hong Kong

Correspondence's Address

Carly SY Lam

Centre for Myopia Research, School of Optometry, The Hong Kong Polytechnic University,

Hung Hom, Hong Kong

E-mail address: carly.lam@polyu.edu.hk

Abstract

Background: We describe two cases of monocular orthokeratology with rapid myopia progression in the contralateral untreated eye during a time that children stopped attending school due to COVID-19 and switched to online mode of learning.

Case reports: An 11-year-old female unilateral myopic anisometropia was fitted with orthokeratology lens only in her left eye. The right eye (non-treated eye) showed myopic progression and axial length elongation while the left eye (orthokeratology treated eye) showed no change in refractive error and axial length changes from Jan 2020 to Jun 2020, which was the class suspension period. The change in myopia (spherical equivalent) was -0.50 D in right eye (non-treated eye) but remain unchanged in the left eye (orthokeratology treated eye). The change in axial length was 0.14 mm in right eye (non-treated eye) and -0.1 mm in the left eye (orthokeratology treated eye) at around 5 months.

A 13-year-old female unilateral myopic anisometropia was fitted with orthokeratology lens in her left eye. The refractive error of each eye was stable before the class suspension, but myopic progression was demonstrated in both eye during class suspension. The change in myopia (spherical equivalent) was -0.75D and -0.50D in right eye (non-treated eye) and left eye (orthokeratology treated eye), respectively. The non-treated eye showed -0.25 D more myopic change than the treated eye in 4-month interval.

Conclusions: Myopia progressed 2 to 5 times faster during lockdown, the change of learning mode and lifestyle under the COVID-19 pandemic are possible risk factors for myopia progression. Protective behaviors and myopia control intervention should be publicized and implemented as prompt as possible.

Key words: anisometropia, COVID-19, myopia control, myopia progression, orthokeratology

Introduction

A new coronavirus caused an outbreak of pneumonia in Wuhan of Hubei Province, China in December 2019. This coronavirus disease was officially named COVID-19 by the World Health Organization (WHO) on February 11, 2020.¹ Since the first case of COVID-19 in Hong Kong was confirmed on Jan 23, 2020,² the government of Hong Kong has implemented a range of public health measures to suppress the local transmission. One of the public health measures was school closure. The Hong Kong Government postponed the class resumption from kindergarten to secondary schools several times and implemented class suspension in tutorial centers. In the light of the local outbreak of COVID-19 in early May, class resumption started from May 20th in several phases.³ Most of the classes in secondary and primary schools resumed in early June of 2020. During the school closures, from late January to mid-June, school children in Hong Kong stopped attending class for at least 4 months. To maintain teaching and learning, many schools and tutorial centers began adapting online teaching during this period. Schools provided online lessons via videoconferencing with schedules similar to that of usual schooldays. In addition, schools provided online assignment to students; students did not only use electronic devices for lessons but also for completing online assignments, causing a dramatic increase in screen time. Besides changing children's learning mode, the outbreak also hinders the school children from spending time outdoor as people preferred staying at home as much as possible.⁴ Near work and lack of outdoor activity are risk factors of myopia.⁵⁻⁹ This paper describes two children with anisometropia fitted with orthokeratology in one eye for myopia control presenting rapid myopic progression in the non-treated eye during the class suspension period.

Case reports

Case 1

In July 2019, an 11-year-old girl was brought to the Optometry Clinic of The Hong Kong Polytechnic University by her parents for a routine eye examination. Unaided visual acuity of the right and left eyes were 6/7.6 and 6/30, respectively. The refractive error was: right eye plano-0.25 x 180, 6/6 and left eye -1.25 -0.25 x 170, 6/6, tested by subjective refraction. The axial length (IOLMaster Ocular Biometer, Zeiss) was 22.55 mm and 22.90 mm in the right and left eyes, respectively. The intraocular pressure was normal, and external and internal ocular health examinations were unremarkable. There was no contraindication for overnight orthokeratology lens wear. Different myopia control measures were explained to the parents, and overnight orthokeratology was chosen.

The orthokeratology fitting session was scheduled in September of 2019; subjective refractive correction was right eye -0.25 -0.25 x 180, 6/6⁺ and left -1.50 -0.50 x 175, 6/6⁺.

Measurements of the horizontal visible iris diameter, keratometric reading, and e-value of the flattest meridian by corneal topography (Medmont E-300) are shown in Table 1. The corneal apex of each eye was found decentered down and temporal.

She was fitted with a Paragon CRT lens (Paragon Vision Sciences) in the left eye only. After instruction on the lens insertion, removal, lens handling and caring, trial lens CRT 7.8-550-33 (base curve-return zone depth-landing zone angle) was dispensed. She returned to the clinic the next morning after 8 hours of overnight lens wear. Left eye unaided visual acuity was 6/7.6⁺² and manifest refractive correction was +0.25 -0.75 x 010, 6/6⁻. Follow-up was scheduled for a week later and slit lamp biomicroscopy revealed good corneal integrity.

Subtractive topographical plots showed a bull's eye pattern but excessive flattening of the cornea (Figure 1a). Left eye unaided visual acuity was 6/9.5⁺³, and the manifest refractive correction was +1.00 -0.50 x 130, 6/6⁻¹. The patient also reported that the near vision was not as clear in the left eye. Therefore, another CRT lens (7.7-550-33) was ordered. She was advised to keep wearing the orthokeratology lens on alternate night while waiting for the new

lens. At the follow-up visit a few weeks later, she had worn the new lens for 3 consecutive nights. Unaided visual acuity was 6/6⁻² and 6/6 in the right and left eyes, respectively. The manifest refractive correction was -0.25 -0.25 x 010, 6/6⁺² and +0.50, 6/6. Axial length was 22.66 mm and 23.00 mm, in the right and left eyes, respectively. External ocular health was unremarkable. She was instructed to wear the orthokeratology lens wear nightly. At a follow-up appointment scheduled a month later in January of 2020, the clinical findings were similar to the last visit, a follow up was planned a month later and then every three months.

However, to avoid crowded places during the local outbreak of COVID-19, the patient missed the February follow up. She returned in June, which was almost 5 months from the last visit, but she consistently wore the overnight lens. Unaided visual acuity was 6/9.6⁻² and 6/6 in the right and left eyes, respectively. Manifest refractive correction was -0.75 -0.25 x 180, 6/6 and +0.25 -0.25 x 090, 6/6⁺. Axial length was 22.82 mm and 22.90 mm. External ocular health was unremarkable. As there was remarkable increase in axial length and myopia in right eye; orthokeratology treatment was also advised for the right eye. The measurements of axial length and manifest refractive error (spherical equivalent) from September 2019 to June 2020 are presented in Figure 2 and Figure 3a, respectively.

Case 2

In April 2018, a 13-year-old girl was brought to a private practitioner for an eye examination. The subjective refractive correction was +0.25 -0.25 x 165, 6/6 and -1.75 -0.25 x 180, 6/6, in the right and left eyes, respectively. The intraocular pressure of each eye was normal, and external and internal ocular health examinations were unremarkable. There was no contraindication for overnight orthokeratology lens wear. Orthokeratology for the left eye was suggested, and fitting was done a week later. Measurements of the keratometric readings and e-value by corneal topography (Keratron Scout) are shown in Table 1.

She was fitted with E-lens (E&E Optics) in the left eye only. After instruction on the lens insertion, removal, and lens care, the E-lens 43.00/10.6/-2.00/Boston XO (Flat K/lens diameter/target power/lens material) was dispensed. She returned to the clinic in the morning after overnight wear for two nights. Left eye unaided visual acuity was 6/6, and the manifest refractive correction was plano -0.25 x 180, 6/6. No corneal staining was found. At the follow-up visit one month later, the unaided visual acuity of each eye was 6/6, and the manifest refractive correction of left eye was +0.50 D, 6/6. Subtractive topographical plots showed a bull's eye pattern (Figure 1b). External ocular health was unremarkable. She was advised to wear the lens on alternate nights and have regular follow ups every three months. The manifest refractive correction was -0.50 D, 6/6 and plano, 6/6, in the right and left eyes, respectively at the follow-up visit in May of 2019. No lens use was advised for the right eye at the visit. The manifest refractive correction was -0.50 D, 6/6 and +0.25 D, 6/6, for the right and left eyes, respectively, at the follow-up visits in September of 2019 and January of 2020. At the follow-up visit in May of 2020, the parents showed their concern about myopic progression as the girl had spent more than ten hours per day on the computer and smart phone for distance learning since the school closure in early February of 2020. Unaided visual acuity was 6/15 and 6/7.5⁺ in the right and left eyes, respectively. The manifest refractive correction was -1.00 -0.50 x 170, 6/6 and -0.25 D, 6/6. External ocular health was unremarkable. Orthokeratology fitting was now done for both eyes. Her right eye and left eye were fitted with E-lens 43.00/10.6 /-1.50/Boston XO and E-lens 43.00/10.6/-2.00/Boston XO, respectively. Her unaided visual acuity was 6/6 in each eye, the manifest refractive correction was plano, 6/6 and +0.25 D, 6/6, and the external ocular health was unremarkable. She was advised to have regular follow-ups every three months. The measurements of manifest refractive correction (spherical equivalent) from April 2018 to June 2020 are presented in Figure 3b.

Discussion

We presented two cases of monocular orthokeratology showing rapid myopic progression in the non-treated eye during the class suspension period (starting from late January 2020).

In the first case, referring to Figure 3a, the refractive correction of the right eye (non-treated eye) was relatively stable before the class suspension. The right eye (non-treated eye) showed remarkable myopic progression and axial length elongation while her left eye (orthokeratology treated eye) showed no change in refractive error and axial length from January 2020 to June 2020 (almost 5 months). The change in myopia (spherical equivalent) was -0.50 D in right eye (non-treated eye) but remained unchanged in left eye (orthokeratology treated eye). The change in axial length was 0.14 mm in right eye (non-treated eye) and -0.1 mm in the left eye (orthokeratology treated eye).

In the second case, referring to the Figure 3b, the refractive correction of each eye was stable before the class suspension, but myopic progression was shown in both eyes during class suspension (January 2020 to May 2020, 4 months). The change in myopia (spherical equivalent) was -0.75 D and -0.50 D in right eye (non-treated eye) and left eye (orthokeratology treated eye) respectively. The non-treated eye showed -0.25 D more myopic change than the treated eye in 4-month interval.

Several studies report that orthokeratology decreases the interocular difference in axial length in anisometropia.¹⁰⁻¹⁴ A retrospective study by Long et al.¹⁰ showed orthokeratology slowed progression of axial elongation in the more myopic eye in both unilateral myopic anisometropes and bilateral myopic anisometropes, compared with anisometropes treated with spectacles, resulting in less difference in axial length between eyes after 1-year orthokeratology treatment. Another retrospective study by Fu et al.¹¹ showed a reduction of interocular difference in axial length occurred in unilateral myopic anisometropes only. The

two cases reported were unilateral myopes fitted with orthokeratology in one eye who showed reduction in the interocular difference in axial length, similar to the studies discussed. However, both the cases had started the orthokeratology treatment prior to the class suspension (February 2020); the myopic progression in the contralateral untreated eye was faster after class suspension was implemented. Tsai et al.¹² found the axial length difference between eyes in a low anisometropia group (less than -2.50 D between eyes) decreased from 0.6 mm to 0.4 mm in 2 years. In the case 1, the axial length difference between eyes decreased from 0.32 mm to 0.08 mm in 5 months; the rate of the change was much faster than demonstrated in the study.¹² We suggest the remarkable reduction of axial length difference between eyes was not only due to the retardation of axial elongation of the more myopic eye by orthokeratology, but also due to the more rapid myopic progression in the contralateral eye.

The rate of progression of the spherical equivalent refraction of myopic children in Hong Kong is about -0.033 D to -0.043 D per month, while the rate of progression of the axial length is about 0.015 mm to 0.02 mm per month.^{15,16} The spherical equivalent refraction of the untreated eye changed -0.11 D/month and -0.18 D/month in the first case and second case, respectively, from January 2020. The axial length of the untreated eye increased 0.031 mm/month in the first case from January 2020. The myopia in terms of spherical equivalent refraction and the axial length of the untreated eyes escalated 2 to 5 times and 2 times, respectively, compared to the general progression in the age-matched children in Hong Kong during class suspension.

We suggest that change of lifestyle is associated with the rapid myopic progression in the cases. To suppress the local transmission of COVID-19, class suspension in school and tutorial centers was implemented from late January to early-June 2020. School children in Hong Kong stopped attending class for at least 4 months. To maintain teaching and learning,

many schools and tutorial centers have been adapting online teaching during this period. School children spent significant time attending online lessons, approximately 6 hours per day,¹⁷ plus doing online assignments and playing games via different kinds of electronic device such as computers, tablets, or smart phones, leading to remarkable increase on the screen time. A meta-analysis found that more time spent on near work activities was associated with higher odds of myopia and that the odds of myopia increased by 2% for every one diopter-hour more of near work per week.⁵ The Beijing Childhood Eye Study⁷, a population-based cross-sectional study of 15,066 children aged seven to eighteen years, showed myopia was associated with longer daily studying duration. A recent longitudinal population-based study found significant lower prevalence of myopia in Taiwan children aged 9-11 years with near work distance >30 cm, discontinuing near work every 30 minutes, and more time outdoors during recess. The authors suggested proper near work behaviors could be helpful in myopia prevention.⁸ Besides changing the learning mode, school closure may also hinder the children spending time outdoors as children often engaged in outdoor activities during recess. Moreover, parents avoided allowing the children to go outside as people preferred staying at home as much as possible during the COVID-19 pandemic,⁴ which may further reduce their time spent outdoors. A meta-analysis found significant negative association between time spent outdoors and prevalence of myopia; the odds of myopia decreased by 2% for every one hour more spent outdoors per week.⁶ A school-based intervention study also showed a significant lower incident rate of myopia and lower rate of myopia progression in children spending their time on outdoor activities during recess.⁹ We believe that the change of learning mode leading to intensive near work, together with reduction of outdoor activity, are associated with the rapid myopia progression in the non-treated eye of these two cases during the COVID-19 pandemic. These case reports do not only reflect the important role of environmental risk factors on myopia, but also raises the

awareness of the importance of myopia control, especially during lockdown. The number of confirmed cases of COVID-19 in Hong Kong raised again in early July 2020 and school closure was implemented again; school closures have been implemented in over 100 countries due to the pandemic.¹⁸ Eye care practitioners should promote visual hygiene to school children and their parents and provide interventions to slow myopia progression as promptly as we can to better ensure the highest quality care.

Conclusion

Myopia progressed faster during lockdown in the presented cases. Visual hygiene and myopia control intervention should be publicized and implemented as prompt soon as possible.

Acknowledgements

The study was supported by ZVN1 (Dean's Reserve, Faculty of Health and Social Science) and 848K, The Hong Kong Polytechnic University.

Conflicts of interest

The authors declare that there is no conflict of interest.

Financial support

None.

References

1. World Health Organization (WHO). Naming the coronavirus disease (COVID-19) and the virus that causes it. Available from: [https://www.who.int/emergencies/diseases/novel-coronavirus-2019/technical-guidance/naming-the-coronavirus-disease-\(covid-2019\)-and-the-virus-that-causes-it](https://www.who.int/emergencies/diseases/novel-coronavirus-2019/technical-guidance/naming-the-coronavirus-disease-(covid-2019)-and-the-virus-that-causes-it) Last Accessed June 15, 2021.

2. Kwok KO, Li KK, Chan HHH, et al. Community Responses during Early Phase of COVID-19 Epidemic, Hong Kong. *Emerg Infect Dis* 2020;26(7):1575-9.
3. Chan E. Arrangements for class resumption in phases for all schools. Available from: http://www.lsy.edu.hk/sites/default/files/files/edb_20200505b_eng.pdf Last Accessed June 15, 2021.
4. Cowling BJ, Ali ST, Ng TWY, et al. Impact assessment of non-pharmaceutical interventions against coronavirus disease 2019 and influenza in Hong Kong: An observational study. *Lancet Public Health* 2020;5(5):e279-e288.
5. Huang HM, Chang DS, Wu PC. The association between near work activities and myopia in children-A systematic review and meta-analysis. *PLoS One* 2015;10(10):e0140419.
6. Sherwin JC, Reacher MH, Keogh RH, et al. The association between time spent outdoors and myopia in children and adolescents: A systematic review and meta-analysis. *Ophthalmology* 2012;119(10):2141-51.
7. You QS, Wu LJ, Duan JL, et al. Factors associated with myopia in school children in China: the Beijing childhood eye study. *PLoS One* 2012;7(12):e52668.
8. Huang PC, Hsiao YC, Tsai CY, et al. Protective behaviours of near work and time outdoors in myopia prevalence and progression in myopic children: A 2-year prospective population study. *Br J Ophthalmol* 2020;104(7):956-61.
9. Wu PC, Tsai CL, Wu HL, et al. Outdoor activity during class recess reduces myopia onset and progression in school children. *Ophthalmology* 2013;120(5):1080-5.
10. Long W, Li Z, Hu Y, et al. Pattern of axial length growth in children myopic anisometropes with orthokeratology treatment. *Curr Eye Res* 2020;45(7):834-8.
11. Fu AC, Qin J, Rong JB, et al. Effects of orthokeratology lens on axial length elongation in unilateral myopia and bilateral myopia with anisometropia children. *Cont Lens Anterior Eye* 2020;43(1):73-7.
12. Tsai WS, Wang JH, Lee YC, Chiu CJ. Assessing the change of anisometropia in unilateral myopic children receiving monocular orthokeratology treatment. *J Formos Med Assoc* 2019;118(7):1122-8.
13. Chen Z, Zhou J, Qu X, et al. Effects of orthokeratology on axial length growth in myopic anisometropes. *Cont Lens Anterior Eye* 2018;41(3):263-6.
14. Na M, Yoo A. The effect of orthokeratology on axial length elongation in children with myopia: Contralateral comparison study. *Jpn J Ophthalmol* 2018;62(3):327-34.
15. Cheung SW, Boost MV, Cho P. Pre-treatment observation of axial elongation for evidence-based selection of children in Hong Kong for myopia control. *Cont Lens Anterior Eye* 2019;42(4):392-8.
16. Lam CS, Tang WC, Tse DY, et al. Defocus Incorporated Soft Contact (DISC) lens slows myopia progression in Hong Kong Chinese schoolchildren: a 2-year randomised clinical trial. *Br J Ophthalmol* 2014;98(1):40-5.
17. Chan HH. South China Morning Post. Coronavirus: Hong Kong students adapt to online learning amid class suspension over pandemic. Available from: https://www.scmp.com/news/hong-kong/education/article/3075280/coronavirus-hong-kong-students-adapt-online-learning-amid?utm_source=copy_link&utm_medium=share_widget&utm_campaign=3075280. Last Accessed August 13, 2020.
18. Viner RM, Russell SJ, Croker H, et al. School closure and management practices during coronavirus outbreaks including COVID-19: A rapid systematic review. *Lancet Child Adolesc Health* 2020;4(5):397-404.

Correspondence regarding this article should be emailed to Carly SY LAM, MSc, PhD, FAAO, at carly.lam@polyu.edu.hk. All statements are the author's personal opinion and may not reflect the opinions of the representative organizations, Optometry & Visual Performance, or any institution or organization with which the author(s) may be affiliated. Permission to use reprints of this article must be obtained from the editor. Copyright 2021 Optometric Extension Program Foundation. OVP is indexed in the Directory of Open Access Journals. Online access is available at www.acbo.org.au, www.oepf.org, and www.ovpjournal.org.

Figure 1a. Subtractive topographical plots of the left eye in the first overnight aftercare of case 1

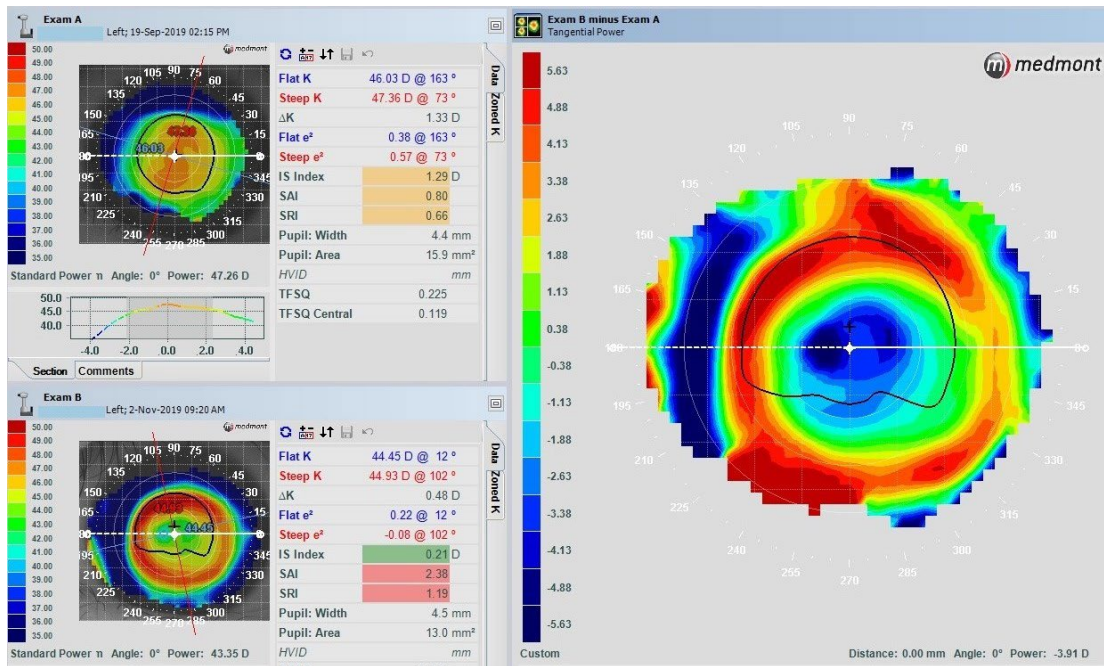


Figure 1b. Subtractive topographical plots of the left eye of case 2

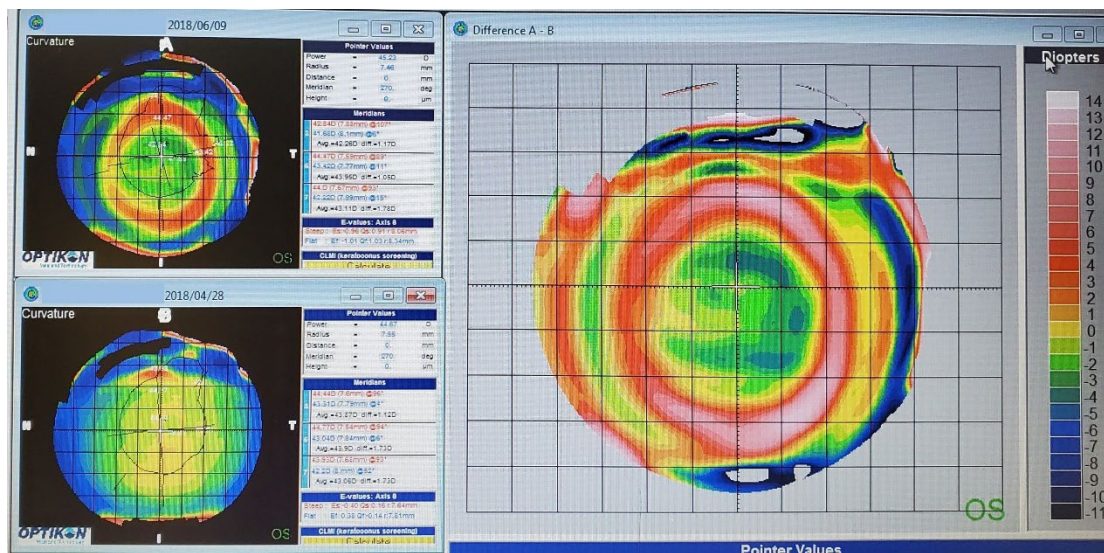
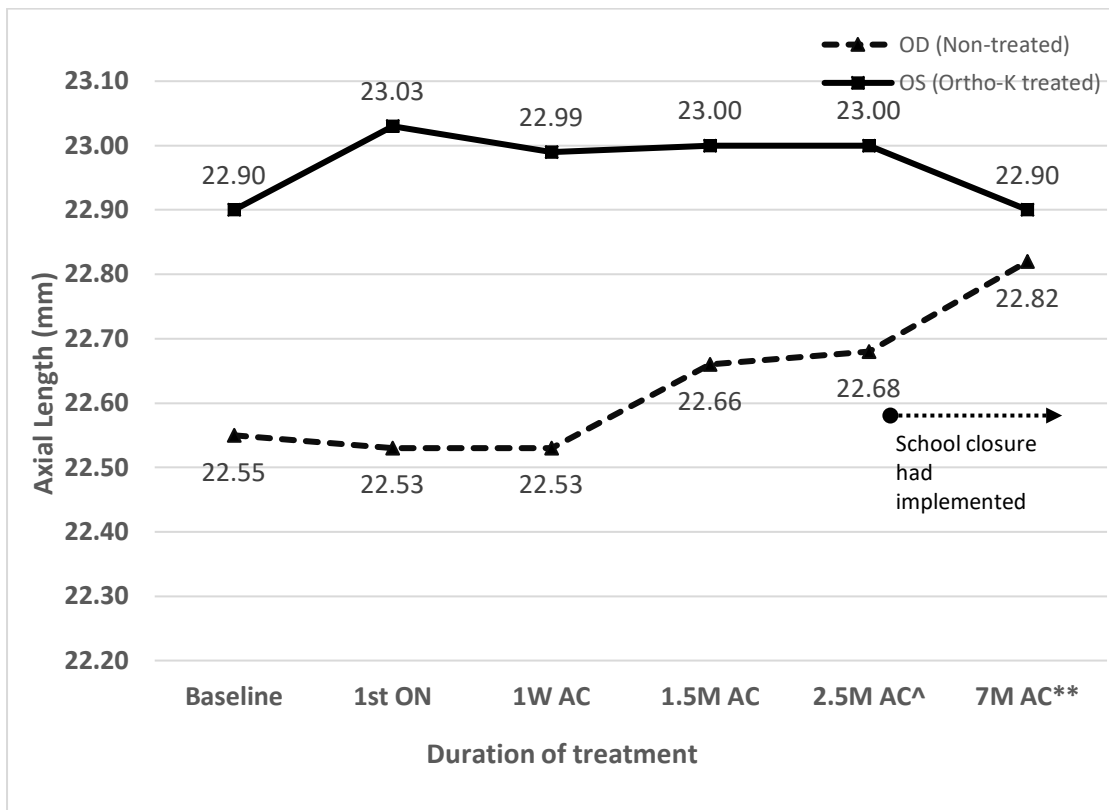


Figure 2. Axial length obtained prior and during treatment with orthokeratology of case 1



1st ON: 1st overnight

1W AC: 1st week aftercare

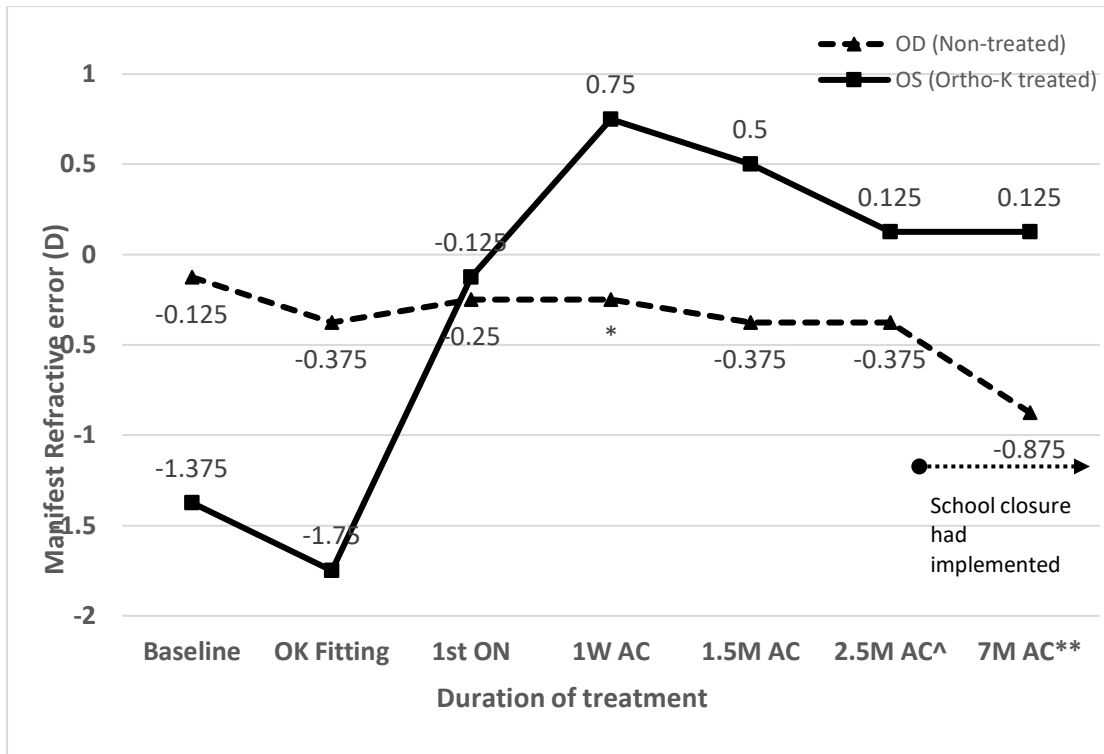
1.5M AC: 1.5-month aftercare

2.5M AC^: 2.5-month aftercare

7M AC**: 7-month aftercare

^ aftercare done on 11 Jan 2020; ** aftercare done on 6 Jun 2020

Figure 3a. Manifest refractive error (spherical equivalent) obtained prior and during treatment with orthokeratology of case 1



OK Fitting: Orthokeratology fitting

1st ON: 1st overnight

1W AC: 1st week aftercare

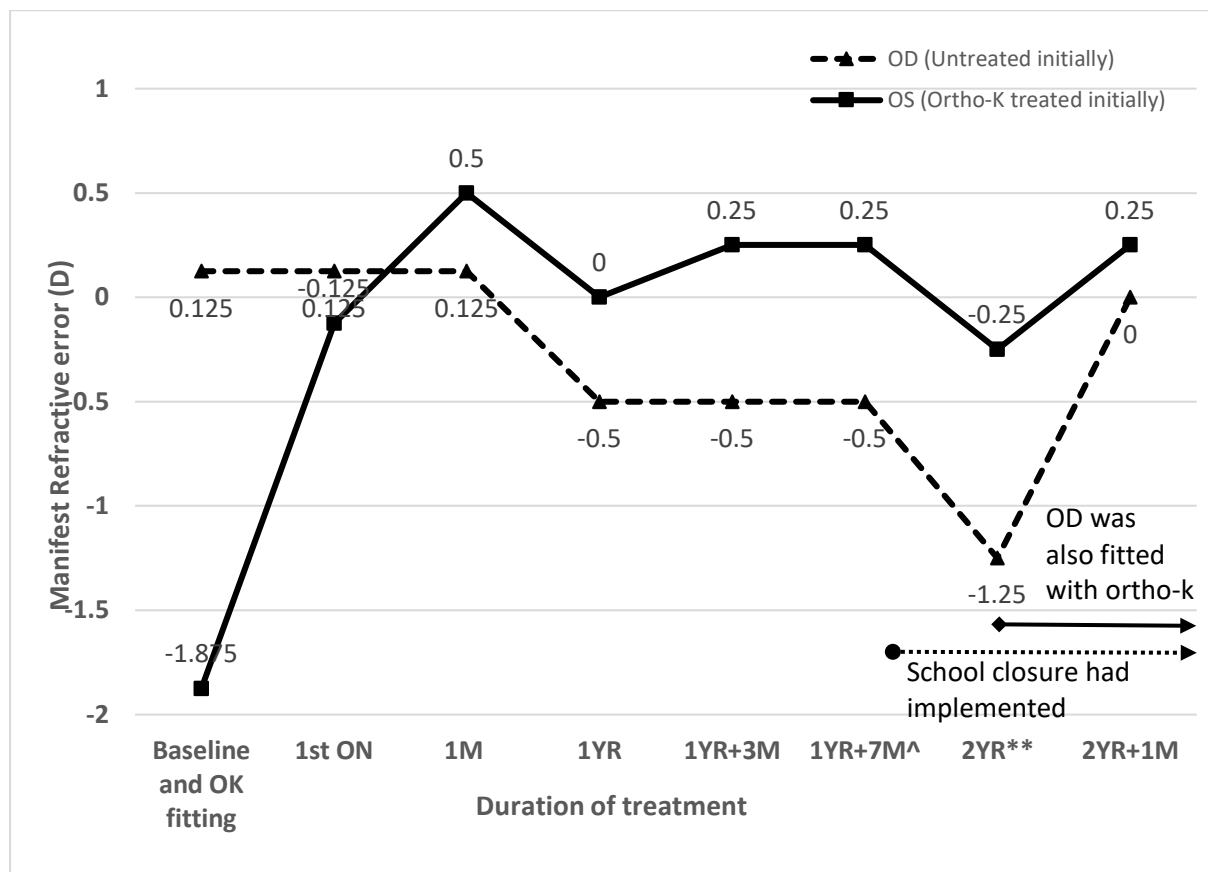
1.5M AC: 1.5-month aftercare

2.5M AC^: 2.5-month aftercare

7M AC**: 7-month aftercare

* No measurement was obtained; ^ aftercare done on 11 Jan 2020; ** aftercare done on 6 Jun 2020

Figure 3b. Manifest refractive error (spherical equivalent) obtained prior and during treatment with orthokeratology of case 2



OK Fitting: Orthokeratology fitting

1st ON: 1st overnight

1M: 1-month aftercare

1YR: 1-year aftercare

1YR+3M: 1 year and 3 months aftercare

1YR+7M: 1 year and 7 months aftercare

2YR: 2-year aftercare

2YR+1M: 2 years and 1 month aftercare

[^] aftercare done on 18 Jan 2020; ^{**} aftercare done on 16 May 2020

Table 1. Measurements of the horizontal visible iris diameter, keratometric reading and e-value of the of the flattest meridian

	Eye	HVID	K-reading	e-value
Case 1	Right eye	11.0 mm	46.00@002	0.64@002
	Left eye	11.0 mm	46.03@163	0.62@163
Case 2	Right eye	Nil	43.16@166	0.27@166
	Left eye	Nil	42.77@006	0.49@006

HVID=horizontal visible iris diameter, K-reading=keratometric reading