

POSTER PRESENTATION

Open Access

Use of 3D prototyping in congenital cardiovascular diseases - initial experience in Hong Kong

Janice J Ip^{1*}, Peter K Hui², Robin Chen³, Eddie Wu⁴, KH Lau⁴, Stephen Cheung¹, TC Yung³, Wendy W Lam¹

From 18th Annual SCMR Scientific Sessions
Nice, France. 4-7 February 2015

Background

The use of 3D prototyping in medical practice is becoming increasingly important, due to the development of 3D printing and the recent rapid advances in relevant techniques and equipments. The use of 3D model is especially important in the field of paediatric cardiology and congenital cardiovascular disease, where there is a clear advantage over conventional 2D images in demonstrating complex anatomies and relationships between different structures.

Methods

The authors have selected a few paediatric cardiovascular diseases, and hope to share their initial experiences in 3D prototyping in this presentation.

Results

Different cases are included to illustrate the use of 3D prototyping in management of congenital cardiovascular diseases.

Conclusions

The departments of radiology and paediatrics of a local teaching hospital and the department of medical engineering of a local university have started the first collaboration in Hong Kong, which pioneered the use of 3D printing in paediatric cardiovascular diseases.

Authors' details

¹Department of Radiology, Queen Mary Hospital, Hong Kong, China.

²Radiology Department, Baptist Hospital, Hong Kong, China. ³Department of

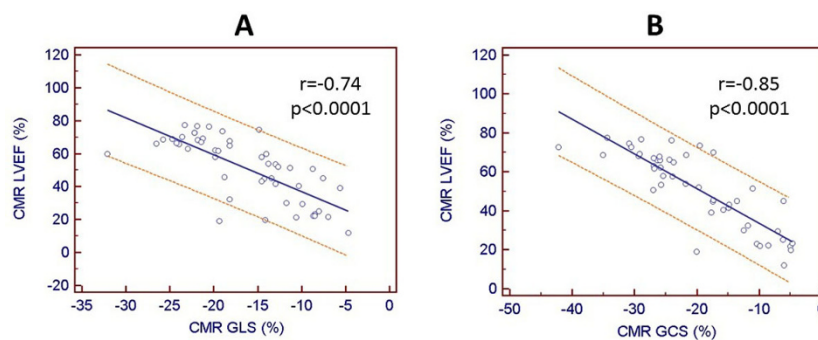


Figure 1

¹Department of Radiology, Queen Mary Hospital, Hong Kong, China
Full list of author information is available at the end of the article

Pediatrics-Cardiology, Queen Mary Hospital, Hong Kong, China. ⁴Department of Industrial and Systems Engineering, Hong Kong Polytechnic University, Hong Kong, China.

Published: 3 February 2015

doi:10.1186/1532-429X-17-S1-P225

Cite this article as: Ip et al.: Use of 3D prototyping in congenital cardiovascular diseases - initial experience in Hong Kong. *Journal of Cardiovascular Magnetic Resonance* 2015 17(Suppl 1):P225.

Submit your next manuscript to BioMed Central and take full advantage of:

- Convenient online submission
- Thorough peer review
- No space constraints or color figure charges
- Immediate publication on acceptance
- Inclusion in PubMed, CAS, Scopus and Google Scholar
- Research which is freely available for redistribution

Submit your manuscript at
www.biomedcentral.com/submit

