https://doi.org/10.3138/ptc.2010-34



**Title:** Changes in bone density and geometry of the upper extremities post-stroke: a case report.

**Authors:** Marco Y. C. Pang, Feigo Z. H. Yang, Ricky W. K. Lau, Ada Q. Cheng, Leonard S.W. Li, Ming Zhang

**Affiliation:**

Marco Y. C. Pang, PhD, PT: Associate Professor, Department of Rehabilitation Sciences, The Hong Kong Polytechnic University, Hong Kong.

Feigo Z. H. Yang, MPT: Department of Rehabilitation Sciences, The Hong Kong Polytechnic University, Hong Kong.

Ricky W. K. Lau, MSc, PT: Department of Rehabilitation Sciences, The Hong Kong Polytechnic University, Hong Kong.

Ada Q. Cheng, MPT: Department of Rehabilitation Sciences, The Hong Kong Polytechnic University, Hong Kong.

Leonard S. W. Li, MD: Head, Division of Rehabilitation Medicine, Tung Wah Hospital, Hong Kong

Ming Zhang, PhD: Professor, Department of Health Technology and Informatics, The Hong Kong Polytechnic University, Hong Kong.

**Corresponding author:**

Marco Y. C. Pang, Department of Rehabilitation Sciences, The Hong Kong Polytechnic University, Hong Kong. Tel: 852-2766-7156, Fax: 852-2330-8656, Email: Marco.Pang@inet.polyu.edu.hk

**Disclosure and conflict of interest:**

The study was supported by the General Research Funds provided by the Research Grants Council, Hong Kong (no. 525607, no. 526708). Ricky W. K. Lau was supported by the Hang Seng Bank Golden Jubilee Research Endowment Fund. Feigo Z. H. Yang and Ada Q. Cheng were supported by full-time MPhil Studentships provided by the Hong Kong Polytechnic University.

**Ethics review:**

Ethics approval of this study was granted by the Research Committee at the Hong Kong Polytechnic University. Written informed consent was obtained by the participant involved before participating in the study.

**ABSTRACT**

**Purpose:** To examine changes in bone density and geometry of the forearm region, and motor function of the paretic upper extremity in an individual with subacute stroke (Participant A).

**Client Description:** Participant A was a 48-year-old man with right hemiparesis.

**Intervention:** Not applicable

**Measures and Outcomes:** The assessment of upper-extremity (UE) function and bone imaging took place at 3 months and 12 months post-stroke. Participant A had moderate motor impairment and severe disuse of the paretic UE 3 months post-stroke. During the follow-up period, no substantial change in paretic UE function was observed. At 12 months follow-up the areal bone-mineral density (aBMD) of the ultradistal and mid regions of the paretic forearm, as measured by dual-energy X-ray absorptiometry, sustained a significant reduction of 7.9% and 5.9%, respectively. The non-paretic side, in contrast, had a significant 4.0% and 2.8% increase in aBMD of the mid-forearm and total forearm. Significant findings from peripheral quantitative computed tomography (pQCT) were a reduction in total volumetric bone mineral density (vBMD) (-12.1%) and bone strength index (-20.6%) in the radius distal epiphysis on the paretic side, and an increase in cortical bone mineral content (+2.0%) and bone strength index (+7.6%) in the radius diaphysis on the non-paretic side.

**Implications:** Following a stroke that resulted in moderate to severe UE impairment, a significant decline in bone-mineral density was identified in various skeletal sites in the forearm region as the patient entered the subacute and chronic stages of recovery. The results point to the potential importance of early rehabilitative intervention in preventing unfavourable bone changes in the paretic upper limb among individuals with stroke.

**Keywords:** cerebrovascular accident, rehabilitation, bone, muscle, fracture, stroke

**INTRODUCTION**

People with stroke are highly susceptible to fragility fractures.[1-4] Post-stroke hip fractures can lead to detrimental consequences such as longer hospital stay, increased disability, and reduced survival rate.[5,6] The costs related to the treatment of fractures also impose considerable economic strain on the health care sector.[7,8] While accidental falls are a major cause of fractures among individuals with stroke,[2,3,9] progressive bone loss after stroke may also be an important contributing factor.[4,10] Fractures in the upper extremity account for 27-36% of all fractures post-stroke, and the majority of these occur on the paretic side.[1,2] Thus, it is clinically relevant to study bone health of the upper extremity in people with stroke.

A number of prospective studies using dual-energy X-ray absorptiometry (DXA) have reported considerable decline in areal bone mineral density (aBMD) in various skeletal sites of the paretic upper extremity following stroke.[11-15] More recent studies have employed peripheral quantitative computed tomography (pQCT) to examine the alterations in bone macrostructure of the upper extremities among individuals with stroke.[16,17] Unlike DXA, which can yield only aBMD values (in g/cm$^2$) because of its planar nature,[18] pQCT measures volumetric BMD (vBMD in mg/cm$^3$) and can analyze trabecular and cortical bone structures separately. It can thus provide valuable information on bone geometry, which is an important determinant of bone strength apart from BMD.[19,20] For example, in the mid-shaft of long bones, the bone structure will be more resistant to externally applied bending or torsional forces if the bone material is distributed further away from the centre (i.e., increased total cross-sectional area), despite the fact that the absolute bone mass and BMD values remain constant.[19] It is therefore important to include geometric parameters in the study of bone health post-stroke.

pQCT was first used to study bone health post-stroke by Ashe et al.[16] Pang et al.[17] later compared the pQCT-derived bone parameters in the mid-shaft radius (a cortical bone site) in a sample of 47 people with chronic stroke; they found that cortical bone mass and cortical area were significantly lower on the paretic side than on the non-paretic side, whereas the total cross-sectional area displayed no significant side-to-side difference.[17] Based on these findings, it was postulated that endosteal resorption (bone loss on the endosteal surface) might have occurred on the paretic side after stroke. Pang et al. further demonstrated that a larger side-to-side difference in cortical thickness, which represents a more seriously compromised bone status on the paretic side, was significantly associated with poorer motor function, more severe spasticity, and disuse of the paretic upper extremity. However, these studies were cross-sectional in nature and cannot demonstrate the actual temporal changes in bone parameters on the paretic and non-paretic sides over time. For example, a significant side-to-side difference could be attributable either to bone changes in the paretic limb or to bone changes in the non-paretic limb.

To date, only one prospective study has examined changes in vBMD of the upper extremities among people with stroke. Lazoura et al.[21] measured patients 3, 6 and 12 months after stroke, and found a significant reduction in trabecular vBMD at the 4% site and cortical vBMD at the 20% site of the paretic radius during the follow-up period. Surprisingly, the degree of bone loss was more severe in men than in women.[21] It is possible that the difference in severity of stroke-related impairments (i.e., motor skills, muscle weakness) between the two genders may explain the findings, but unfortunately these were not measured in the study. Changes in bone geometry (e.g., total cross-sectional area, cortical bone area, etc.) were also not reported. Therefore, it remains unknown whether resorption/apposition actually occurred at the endosteal or/and periosteal surfaces of the bone in these subjects as stroke recovery progressed.

No study has yet examined the longitudinal changes in aBMD, vBMD, and bone geometry of the upper extremities in the same stroke patients, with clear documentation of data on changes in various aspects of physical functioning (e.g., motor skills, muscle strength, spasticity, and disuse) of the affected upper extremity and environmental factors (e.g., therapy) that may be highly related to bone loss.[17,22] In this case report, we aim to describe the longitudinal changes in bone parameters of the paretic and non-paretic upper extremities of an individual with stroke. Changes in functional status of the paretic upper limb were also carefully documented. The findings may shed some light onto the temporal changes in bone density and geometry of the upper limb post-stroke and the key associated clinical factors.

## CASE DESCRIPTION

Relevant information (e.g., medical history, medications) was obtained by subject interview and the discharge summary issued to Participant A by the hospital. Ethics approval for this study was granted by the Hong Kong Polytechnic University, and written informed consent was obtained from the subject before his participation in the study.

Participant A was a 48-year-old man (height: 1.77 m, weight: 88.6 kg, body mass index [BMI]: 28.3 kg/m$^2$) with a history of obesity, type 2 diabetes mellitus, hyperlipidemia, and hypertension. He experienced a sudden onset of right-sided weakness, dizziness, and slurring of speech in January 2009; he was admitted to a local hospital immediately, and the computed tomography (CT) scan revealed infarcts in the left lentiform nucleus extending to the caudate nucleus with involvement of the posterior limb of the external capsule. Physiotherapy treatment (2 hours per day) began on day 5 post stroke and included gait retraining and upper- and lower-limb strengthening exercises. He was discharged home on day 13, at which point he began to receive 3 hours of physiotherapy and 3 hours of occupational therapy per day, 2 days per week, at a day hospital. The 12-week rehabilitative treatment involved a variety of flexibility, mobility, endurance, and strengthening exercises. After therapy was terminated, he continued to perform

home exercises (i.e., walking, self-stretching exercises of the upper and lower limbs) for a total of 40 minutes per day. His prescribed medications included Aspirin (an anti-platelet agent), Metformin (an anti-diabetic agent), Glicazide (an anti-diabetic agent), Famotidine (an anti-histamine agent), Simvastatin (a hypolipidemic agent), and Perindopril tertbutylamine (an antihypertensive agent). Participant A was right-hand dominant.

**OUTCOME MEASURES**

Participant A underwent the following outcome measurements at 3 and 12 months after the onset of stroke. All assessment procedures were standardized and were conducted by the same research personnel, who had relevant experience.

*Muscle strength*

Hand grip strength was measured using the Jamar dynamometer (Sammons Preston, Mississauga, ON). The subject was tested while sitting upright in a chair, with the shoulder adducted and neutrally rotated, elbow joint flexed at 90° in neutral supination and pronation, and wrist in a neutral position. A total of three trials were performed on each side, and the data were averaged to obtain the mean hand grip strength value (in kg) for the paretic and non-paretic sides. Hand-held dynamometry has been shown to be a reliable method of testing muscle strength in people with stroke in previous studies.[23] Our data on 37 chronic stroke subjects (mean age: 61.1 years, SD = 9.4 years) also show excellent test-retest reliability of the grip strength measurement for both the paretic and non-paretic sides (intra-class correlation coefficient [ICC] = 0.95), with minimal detectable change (MDC) values (i.e., the smallest difference that would reflect a real change) of 5.2 kg and 5.0 kg for the paretic and non-paretic sides respectively.

*Motor function*

The Fugl-Meyer Motor Assessment (FMA) was used to assess motor function of the affected upper extremity. The FMA is based on the performance of 33 tasks that evaluate the quality and coordination of movements and reflex activity. A score from 0 to 2 is given for each task, with a higher score indicating better recovery of upper-extremity motor function (maximum score = 66). FMA is a reliable measure of motor recovery in patients with stroke.[24]

*Disuse*

The amount of use scale in the Motor Activity Log (MAL) was used to assess how much the subject used the paretic upper extremity in daily activities.[25] The MAL consists of 30 functional tasks (e.g., putting on shoes, brushing teeth), each rated on a scale ranging from 0 (paretic arm not used) to 5 (paretic arm used

as much as before the stroke). The scores for the 30 items are averaged to obtain a mean MAL score. The MAL has been shown to have good internal consistency and construct validity when used in individuals with stroke. [25]

*Spasticity*

The Modified Ashworth Scale (MAS) was used to assess resistance to passive elbow flexion/extension movements on the paretic side. The MAS is scored on a six-point scale from 0 (no increase in muscle tone) to 4 (affected part rigid in flexion and extension). The MAS is a reliable tool to evaluate muscle tone in the stroke population.[26]

*Dual-energy X-ray absorptiometry*

The subject underwent a total forearm scan using DXA (Hologic Inc, Bedford, MA). All scans were conducted by the same operator, using standard procedures as described in the Hologic users' manual. The aBMD (g/cm$^2$) values of different regions of the forearm—the ultradistal region, mid-region, and 1/3 region—as well as the total forearm were determined by the region of interest (ROI) programme (see Table 1).

*Peripheral quantitative computed tomography*

The vBMD and geometric properties of the mid-shaft radius were measured by pQCT (Stratec Medizintecnik XCT 3000, software version 6.00B, Pforzheim, Germany). The length (mm) of the radius on each side was measured as recommended by the manufacturer.[27] After proper positioning, a scout view was obtained and the anatomical reference line was placed at the cortical end plate of the distal radius. A 2.3 mm scan of the distal epiphysis (4% of the total bone length proximal to the reference line, primarily trabecular bone) and diaphysis (33% of the total bone length proximal to the reference line, primarily cortical bone) was obtained on each side, with a scan speed of 20 mm/s and an in-plane pixel size of 500 microns. Studying the distal epiphysis of the radius was clinically relevant, as this is a common site of fracture in individuals with stroke (i.e., Colles fracture).[2] The radius diaphysis was also chosen for measurement because of its anatomical proximity to the origin/insertion of many important muscle groups (e.g., extensor pollicis brevis, pronator teres, abductor pollicis longus),[17] as a result of which motor impairment, paresis, and spasticity may potentially have more influence on this site. All image analyses were performed using the XCT version 6.00B software. For analysis of the 4% site, the CALCBD function (Contour mode 2, peel mode 2) with density thresholds of 169/400 mg/cm$^3$ was used. This means we detected the outer contour of the bone at the 4% radius site using a density threshold of 169mg/cm$^3$ and separated trabecular from (sub)cortical bone using 400mg/cm$^3$. [27] For cortical bone

analysis of the 33% site, the CORTBD function (Mode 1) with threshold of 710 mg/cm$^3$ was used. This means that densities greater than 710mg/cm$^3$ at the 33% radius site were defined as cortical bone. [27]

For the distal epiphysis (4% site), the variables of interest were total area (ToA, mm$^2$), total vBMD (mg/cm$^3$), and trabecular vBMD (mg/cm$^3$). A compressive bone strength index (cBSI, mg$^2$/mm$^4$) was calculated based on the following formula:

$$\text{ToA} \times (\text{total vBMD})^2$$

The cBSI indicates the strength of the bone segment against compressive forces, which is appropriate because long-bone epiphysis is primarily subjected to axial compression.[28,29] The cBSI has been used in other studies to estimate strength of the distal end of long bones.[29,30] Indeed, a human cadaver study showed that at the 4% tibial site, the cBSI is an excellent determinant of failure load, accounting for 85% of variance.[31]

For the radius diaphysis (33% site), the variables of interest were total area (ToA, mm$^2$), cortical bone area (CoA, mm$^2$), cortical bone mineral content (BMC, mg/cm), cortical vBMD (mg/cm$^3$), and cortical thickness (mm). Marrow cavity area (CavA, mm$^2$) was derived by subtracting CoA from ToA. In addition, the polar stress–strain index (p-SSI, mm$^3$) was also generated by the pQCT. The p-SSI is used to indicate bone strength against torsional loads in long bone shafts,[17,29,30,32] and was computed by the system using the following formula:[33]

$$\text{p-SSI} = \sum \frac{[(A_z \times d_z^2)(BMD_{cort}/ND)]}{d_{max}}$$

where *A* represents the area of each pixel, $d_z$ is the distance between the pixel and the corresponding torsion (*z*) axis, ND is the normal physiological bone density (1200mg/cm$^3$), and $d_{max}$ is the maximum distance to the centre of gravity. The p-SSI in the radial diaphysis has been found to be highly correlated to the failure load when the bone is loaded in three-point bending, and is therefore considered a valid indicator of bone strength.[34,35]

Review by the technician and principal investigator determined that all scans were of sufficient quality to be used for analysis. To determine the precision of our DXA and pQCT scanners, 30 healthy individuals were scanned twice, with repositioning after the first scan. The least significant change (LSC) values for the aforementioned outcomes of interest were calculated, according to the guidelines set by the International Society for Clinical Densitometry (see Table 1).[36] Changes exceeding the LSC values were considered statistically significant.

## PATIENT OUTCOMES

### Upper-extremity function

The results for muscle strength, motor function, disuse, and spasticity are illustrated in Figure 1. At baseline assessment, 3 months post-stroke, hand-grip strength (Figure 1A) was considerably lower on the paretic side (8 kg) than on the non-paretic side (35.3 kg), reflecting considerable muscle weakness on the paretic side. During the follow-up period, the paretic side showed a slight increase in hand-grip strength (+2.3 kg), whereas the non-paretic side suffered a reduction in the same variable (-4.6 kg). However, these change values were below the established MDC values and thus not statistically significant. Results of initial assessment with the FMA (Figure 1B) and MAL (Figure 1C) also indicated moderately impaired motor function and severe disuse of the paretic upper extremity. Subject A also presented with mild spasticity in the paretic upper extremity (MAS score = 1) at initial assessment (Figure 1D). During the follow-up period, no substantial change was identified in any of these outcomes in the paretic upper extremity (see Figure 1B–D).

**DXA parameters: forearm areal bone mineral density**

There were differential changes in forearm aBMD between the paretic and non-paretic sides across time. aBMD declined significantly in the ultradistal forearm (-7.9%), mid-forearm (-5.0), and total forearm (-4.8%) on the paretic side (see Table 2); in contrast, the non-paretic side demonstrated a significant increase in aBMD of the mid-forearm (+4.0%) and total forearm (+2.8%).

**pQCT: volumetric bone mineral density and geometry of the radius epiphysis**

During the follow-up period, the radius epiphysis (4% site) on the paretic side showed a significant reduction in total vBMD (-12.1%) (see Table 3). ToA, the main geometric parameter, did not change significantly over time. Despite this, the decline in total vBMD was substantial enough to cause a significant 20.6% decline in cBSI. In contrast, none of the pQCT parameters showed any significant changes on the non-paretic side.

**pQCT: volumetric bone mineral density and geometry of the radius diaphysis**

The patterns of bone alterations in the radius diaphysis (33% site) were distinct from those in the radius epiphysis. Interestingly, no significant changes were found in any of the pQCT densitometric and geometric parameters on the paretic side (see Table 3). On the non-paretic side, however, significant increases in cortical BMC (+2.0%) and p-SSI (+7.6%) were identified. As in the radius epiphysis, the various geometric parameters on the non-paretic side did not show any significant change over time on either side.

**DISCUSSION**

This case report presents an individual with moderately impaired upper-extremity function. While the motor function and amount of habitual use of the paretic upper extremity displayed no substantial changes over time, bone density of the target skeletal sites, as measured by DXA and pQCT, demonstrated distinct patterns of alterations between the paretic and non-paretic sides.

**Areal bone mineral density of the forearm**

The DXA results showed a significant decrease in aBMD of the ultradistal and mid-regions of the paretic forearm by 7.9% and 5.0%, respectively. This finding concurs with previous prospective studies of individuals with stroke,[11-15] which have also reported progressive decline in aBMD in other skeletal sites of the paretic upper extremity. Interestingly, there was a 4.0% increase in mid-forearm aBMD on the non-paretic side. This finding is consistent with those of Ramnemark et al.:[11] in their 1-year prospective study of a group of individuals with acute stroke, they reported a significant reduction in aBMD (7.6–17.4%) at various skeletal sites of the paretic upper extremity (e.g., humerus, total arm) but an increase in aBMD at these sites on the non-paretic side (3.6–5.5%). The progressive decline of forearm aBMD observed in our study may be explained by severe motor impairment and disuse on the paretic side, as reflected in the large side-to-side difference in grip strength, low FMA, and MAL scores. It is thought that the concomitant increase in non-paretic forearm aBMD may be related to the compensatory increased use of the non-paretic upper limb in performing daily functional activities.[11,17] Participant A's dominant upper extremity was affected by his stroke, and the amount of paretic upper limb use was extremely limited, as reflected in the low MAL score (< 1.0). It can thus be inferred that many important daily activities assessed in the MAL that normally involve only the dominant hand (e.g., brushing teeth, using a key to open a door) had to be performed using the non-dominant (non-paretic) upper extremity, although we did not have an objective measurement of non-paretic upper limb use.

**Densitometric and geometric changes in the radius epiphysis**

Our results show that the paretic radius epiphysis underwent significant bone loss; in particular, the total vBMD sustained an impressive 12.1% decline during the follow-up period. Interestingly, however, the decline in trabecular vBMD was not statistically significant. Taking these findings together, it is reasonable to suggest that the overall reduction in total vBMD may be mainly attributable to reduced bone density in the cortex, although we did not use cortical vBMD or cortical thickness as outcome measures at the radius epiphyseal site because of the partial volume effect (see limitations below).

The ToA did not demonstrate any significant change. Despite the lack of change in overall bone size, the decline in total vBMD on the paretic side led to a significant reduction in cBSI, indicating that the bone segment was becoming less resistant to externally applied compressive loads over time. This is

clinically relevant because the wrist region is the second most common site of fracture among stroke patients.[2] On the non-paretic side, in contrast, none of the pQCT parameters showed significant changes during the follow-up period. Overall, these findings are consistent with findings for the ultradistal forearm region using DXA, as described above.

Using a prospective study design, Lazoura et al.[21] found that the trabecular vBMD decreased by 14.0% and 6.8% on the paretic and non-paretic sides, respectively, between 3 and 12 months post-stroke in a group of 43 men. No data on geometric properties were reported, but the decline in vBMD on the two sides contributed to a corresponding decrease in p-SSI (28.6% and 11.5% respectively). We did not observe a significant reduction in trabecular vBMD on the paretic side in Subject A, nor did we detect any significant changes in the vBMD or bone strength index on the non-paretic side. However, it is difficult to compare our findings with those of Lazoura et al.,[21] not only because our data are derived from a single stroke patient but because Lazoura et al. did not provide the details on participants' upper-extremity function and because the bone strength index used was different from ours. We feel that it is more appropriate to use cBSI, rather than p-SSI, for the epiphyseal region, as compressive forces are more predominant the distal radius epiphysis.[28] Indeed, a study of older adults showed that while maximal voluntary isometric, concentric, or eccentric hand grip torques accounted for 78-90% of the variance in p-SSI at the radius diaphysis, these muscle torques could only predict 38-42% of the variance in CBSI at the distal radius epiphysis,[37] indicating that torsional forces from muscle contractions play a lesser role in determining bone strength at the distal radius epiphysis.

**Densitometric and geometric changes in the radius diaphysis**

Compared with the radius epiphysis, bone changes in the radius diaphysis on the paretic side were unremarkable. Although there was a trend toward decline in cortical BMC (-1.4%) in the radius diaphysis on the paretic side, the change did not reach statistical significance (LSC = 1.913%). This is surprising, given that cortical bone sites may be more influenced by muscle loading, and hence more susceptible to bone loss as a result of disuse and muscle weakness. It is possible that substantial bone loss had already taken place within the first 3 months post-stroke and was not captured by our measurements. It is also possible that tonic muscle activity associated with spasticity may have some protective effect on bone. Moreover, epiphyseal and diaphyseal bone sites may respond differently to unloading. For example, a study of cosmonauts revealed that trabecular bone at the distal tibial epiphysis showed earlier and more pronounced bone loss than cortical bone at the tibial diaphysis in response to microgravity exposure in space flight.[38]

The non-paretic side, on the other hand, showed some favourable bone changes. There was a significant increase in cortical BMC, leading to an increase in p-SSI, during the follow-up period. As

mentioned previously, the increase in bone mass and bone strength on the non-paretic side during the follow-up period may have been due to increased motor activity on this side as a compensatory strategy.

Our finding in the radius diaphysis contrasts with that of Lazoura et al.,[21] who reported a significant decline in cortical vBMD at the 20% radius site on both sides (1.7–4.0%) between 3 and 12 months post-stroke in their male participants. Again, it is difficult to compare our findings with theirs because no details on recovery of upper extremity function were provided and because the site of measurement was different.

It is intriguing that none of the geometric parameters showed significant changes over time. A previous cross-sectional study in chronic stroke showed a significant side-to-side difference in cortical bone area but not in ToA, suggesting endosteal resorption on the paretic side.[17] Our results, however, do not support this hypothesis. While the ToA in both the radius epiphysis and the radius diaphysis showed an increasing trend, the results did not reach statistical significance. Perhaps a longer follow-up period is required to examine alterations in bone geometry post-stroke. We also cannot rule out the possibility that any new bone added to the periosteal surface could not be accurately captured because a relatively high threshold (710 mg/cm$^3$) was used for the total bone analysis in the radius diaphysis.

**IMPLICATIONS**

This case report has important clinical implications. First, the paretic upper extremity of Participant A, which had moderate motor impairment and severe disuse, sustained detrimental bone changes. While traditional stroke rehabilitation has focused primarily on restoring neuromotor function, our data suggest that bone-health status in the upper limb merits more attention during the rehabilitation process. Previous studies have suggested a relationship between bone densitometric and geometric parameters of the radius and various aspects of stroke impairments (motor function, muscle strength, disuse, spasticity). It is important to determine whether treatment aimed at improving motor skills (e.g., task oriented training), strengthening the muscles (e.g., resistance training, electrical muscle stimulation), promoting active use of the paretic upper limb (e.g., constraint-induced movement therapy), or reducing spasticity at different stages of stroke recovery can maintain/enhance BMD and bone geometry in the upper extremity.

Second, the results showed that although the pattern of upper limb motor function and disuse remained relatively stable during the follow-up period, aBMD of the forearm and cBSI of the radius epiphysis continue to decline. It is likely that initial functional status of the paretic upper extremity is an important factor in determining subsequent bone changes as the patient enters the chronic stage of stroke recovery. It has been shown that severity of functional impairment in the upper extremity measured in the acute stage is a powerful predictor of 1-year aBMD decline in the humerus among stroke patients.[14] Our

results thus point to the potential importance of early rehabilitative intervention in preventing unfavourable bone changes among individuals with stroke.

## LIMITATIONS AND FUTURE DIRECTIONS

This case report has several limitations. First, the external validity of our results is limited. The characteristics of Participant A are not representative of the general stroke population, and therefore our findings may not be applicable to other individuals with stroke. A larger sample of people with stroke, and a group of age- and sex-matched healthy individuals, should be used in future research to determine the association of stroke impairments with bone densitometric and geometric changes.

Second, bone changes during the acute stage remain uncertain. Participant A was referred to our research team by the Community Rehabilitation Network (CRN), a large organization in Hong Kong that coordinates ambulatory rehabilitation services for people with stroke; patients typically do not commence their programmes at CRN until they have completed inpatient rehabilitation and are well settled in their own homes after discharge from hospital, which is why we could not perform our assessments during the acute stage of stroke. Future studies should address bone changes during the acute stage of stroke recovery and determine which stroke impairment at baseline is the most important determinant of bone changes over time.

Third, one limitation of the pQCT scanner is the possibility of a *partial volume effect*, which occurs when there is heterogeneous material within a single voxel (volumetric pixel). In areas where cortical bone is thin (< 2mm), including epiphyseal sites on the paretic side in stroke patients, voxels may only be partly filled by bone material and soft tissues; these voxels will falsely yield lower density values, because a voxel's value is the mean density of all the tissues within it.[33,39]

Finally, the question of whether modification of stroke impairments can counteract the bone changes observed following stroke awaits further research. There is some evidence that proper exercise training can maintain BMD and enhance bone geometry in the lower extremity among patients with chronic stroke.[40-42] Future randomized controlled intervention trials are required to investigate the effects of different treatment regimens on bone outcomes following stroke.

## KEY MESSAGES

### What is already known on this subject:

A number of studies have demonstrated progressive aBMD decline in various skeletal sites of the paretic upper extremity among individuals with stroke.[11-15] However, only one prospective cohort study has used pQCT to examine bone changes in stroke patients and found a significant decline in vBMD in the radius

epiphysis and diaphysis on both sides.[21] Cross-sectional studies have revealed a significant relationship between bone densitometric/geometric parameters in the radius diaphysis and stroke-specific impairments such as muscle strength, spasticity, motor recovery, and disuse among patients with chronic stroke.[16,17]

**What this study adds:**

On the paretic side, the aBMD of the forearm region and vBMD of the radius epiphysis continued to decline significantly even though no changes in paretic upper extremity function were observed between 3 and 12 months post-stroke. The radial diaphysis on the paretic side showed no significant changes in bone mass within the first year post-stroke, whereas that on the non-paretic side demonstrated a significant increase in the same variable, as measured by pQCT. No significant geometric changes were observed in the radius epiphysis or diaphysis on either side.

**REFERENCES**


1. Ramnemark A, Nyberg L, Borssen B, Olsson T, Gustafson Y. Fractures after stroke. Osteoporos Int. 1998;8:92–5.
2. Dennis MS, Lo KM, McDowall M, West T. Fractures after stroke: frequency, types and associations. Stroke. 2002;33:728–34.
3. Kanis J, Oden A, Johnell O. Acute and long-term increase in fracture risk after hospitalization for stroke. Stroke. 2001;32:702-706.
4. Eng JJ, Pang MYC, Ashe MA. Balance, falls, and bone health: Role of exercise in reducing fracture risk after stroke. J Rehabil Res Dev. 2008;45:297-314.
5. Di Monaco M, Vallero F, Di Monaco R, Mautino F, Cavanna A. Functional recovery and length of stay after hip fracture in patients with neurologic impairment. Am J Phys Med Rehabil. 2003;82:143-8.
6. Ramnemark A, Nilsson M, Borssén B, Gustafson Y. Stroke, a major and increasing risk factor for femoral neck fracture. Stroke. 2000;31:1572-7.
7. Kanis JA, Johnell O. Requirements for DXA for the management of osteoporosis in Europe. Osteoporos Int. 2005;16:229-38.
8. Stevenson M, Davis SE, Kanis JA. The hospitalization costs and outpatient costs of fragility fractures. Wom Health Med. 2006;3:149-51.
9. Whitson HE, Pieper CF, Sanders L, Horner RD, Duncan PW, Lyles KW. Adding injury to insult: Fracture risk after stroke in veterans. J Am Geriatr Soc. 2006;54:1082-8.
10. Poole, KES; Reeve, J; Warburton, EA. Falls, fractures, and osteoporosis after stroke: Time to think about protection? Stroke. 2002;33:1432-6.
11. Ramnemark A, Nyberg L, Lorentzon R, Englund U, Gustafson Y. Progressive Hemiosteoporosis on the paretic side and increased bone mineral density in the nonparetic arm the first year after severe stroke. Osteoporos Int. 1999;9:269-75.
12. Ramnemark A, Nyberg L, Lorentzon R, Olsson T, Gustafson Y. Hemiosteoporosis after severe stroke, independent of changes in body composition and weight. Stroke. 1999;30:755-60.
13. Liu M, Tsuji T, Higuchi Y, Domen K, Tsujiuchi K, Chino N. Osteoporosis in hemiplegic stroke patients as studied with dual-energy X-ray absorptiometry. Arch Phys Med Rehabil. 1999;80:1219-26.
14. Jorgensen L, Jacobsen BK. Functional status of the paretic arm affects the loss of bone mineral in the proximal humerus after stroke: a 1-year prospective study. Calcif Tissue Int. 2001;68:11-5.
15. Yavuzer G, Ataman S, Sulder N, Mesut A. Bone mineral density in patients with stroke. Int J Rehabil Res. 2002;25:235-9.

16. Ashe MC, Fehling P, Eng JJ, Khan KM, McKay HA. Bone geometric response to chronic disuse following stroke: a pQCT study. J Musculoskelet Neuronal Interact. 2006;6:226-33.
17. Pang MYC, Ashe MA, Eng JJ. Muscle weakness, spasticity and disuse contribute to demineralization and geometric changes in the radius following chronic stroke. Osteoporos Int. 2007;18:1243-52.
18. Melton III LJ. The prevalence of osteoporosis: gender and racial comparison. Calcif Tissue Int. 2001;69:179-81.
19. Turner CH, Burr DB. Basic biomechanical measurements of bone: a tutorial. Bone. 1993;14:595-608.
20. Frost HM. Absorptiometry and "osteoporosis": problems. J Bone Miner Metab. 2003;21:255-60.
21. Lazoura O, Groumas N, Antoniadou E, Papadaki PJ, Papadimitriou A, Thriskos P, *et al*. Bone mineral density in upper and lower extremities 12 months after stroke measured by peripheral quantitative computed tomography and DXA. J Clin Densitom. 2008;11:511-7.
22. Pang MYC, Eng JJ. Muscle strength is a determinant of bone mineral content in the hemiparetic upper extremity: implications for stroke rehabilitation. Bone. 2005;37:103-11.
23. Bohannon RW. Measurement and nature of muscle strength in patients with stroke. J Neuro Rehabil. 1997;11:115-25.
24. Sanford J, Moreland J, Swanson LR, Stratford PW, Gowland C. Reliability of the Fugl-Meyer assessment for testing motor performance in patients following stroke. Phys Ther. 1993;73:447-54.
25. van der Lee JH, Beckerman H, Knol DL, de Vet HC, Bouter LM. Clinimetric properties of the Motor Activity Log for the assessment of arm use in hemiparetic patients. Stroke. 2004;35:1410-4.
26. Bohannon RW, Smith MB. Interrater reliability of a modified Ashworth scale of muscle spasticity. Phys Ther. 1987;67:206-7.
27. Stratec Medizintechnik GmbH. XCT 3000 Manual. Software version 6.00. Pforzheim, Germany: Stratec Medizintechnik GmbH; 2004.
28. Hayes W, Bouxsein ML. Biomechanics of cortical and trabecular bone: implications for assessment of fracture risk. Basic orthopaedic biomechanics. Philadelphia: Lippincott-Raven Publishers; 1997.
29. Kontulainen S, Sievanen H, Kannus P, Pasanen M, Vuori L. Effect of long-term impact-loading on mass, size, estimated strength of humerus and radius of female racquet-sports players: a peripheral quantitative computed tomography study between young and old starters and controls. J Bone Miner Res. 2002;17:2281-9.
30. Macdonald HM, Kontulainen S, Petit M, Hughes JM, Beck TJ, McKay HA. Bone strength and its determinants in pre-and early pubertal boys and girls. Bone. 2006;39:598-608.
31. Kontulainen SA, Johnston JD, Liu D, Leung C, Oxland TR, McKay HA. Strength indices from pQCT imaging predict up to 85% of variance in bone failure properties at tibial epiphysis and diaphysis. J Musculoskelet Neuronal Interact. 2008;8:401-9.

32. Pang MYC, Ashe MA, Eng JJ. Tibial bone geometry in chronic stroke patients: influence of gender, cardiovascular health, and muscle mass. J Bone Miner Res. 2008;23:1023-30.
33. Leonard MB, Shore RM. Radiologic evaluation of bone mineral in children. In: Favus MJ, editor. Primer on the metabolic bone disease and disorders of mineral metabolism. 5th ed. Washington DC: American Society for Bone and Mineral Research; 2003. p. 173-189.
34. Lochmuller EM, Lill CA, Kuhn V, Schneider E, Eckstein F. Radius bone strength in bending, compression, and falling and its correlation with clinical densitometry at multiple sites. J Bone Miner Res. 2002;17:1629-38.
35. Wilhelm G, Felsenberg D, Bogusch G. Biomechanical examinations for validation of the Bone Strength-Strain Index SSI, calculated by peripheral quantitative computed tomography. In: Lyrithis GP, editors. Musculoskeletal interactions. Vol II. Athens: Hylonome; 1999. p. 105-111.
36. iscd.org/Visitors/positions/OfficialPositionsText.cfm [Internet]. International Society of Clinical Densitometry Inc., c2011 [updated 2010 Dec 11, cited 2011 Feb 18]. Available from: http://www.iscd.org/Visitors/positions/OfficialPositionsText.cfm.
37. Frank AW, Lorbergs AL, Chilibeck OPD, Farthing JP, Kontulainen SA. Muscle cross sectional area and grip torque contraction types are primarily related to pQCT derived bone strength indices in the radii of older healthy adults. J Musculoskelet Neuronal Interact. 2010;10:136-41.
38. Vico L, Collet P, Guignandon A, Lafage-Proust, Thomas T, Rehailia M, Alexandre C. Effects of long-term microgravity exposure on cancellous and cortical weight-bearing bones of cosmonauts. Lancet. 2000;355:1607-11.
39. Hangartner TN, Gilsanz V. Evaluation of cortical bone by computed tomography. J Bone Miner Res. 1996;11:1518-25.
40. Pang MYC, Lau RWK. The effects of treadmill exercise training on hip bone density and tibial bone geometry in stroke survivors: a pilot study. Neurorehabil Neural Repair. 2010;24:368-76.
41. Pang MYC, Eng JJ, Dawson AS, McKay HA, Harris JE. A community-based fitness and mobility exercise program for older adults with chronic stroke: A randomized, controlled trial. J Am Geriatr Soc. 2005;53:1667-74.
42. Pang MYC, Ashe MC, Eng JJ, McKay HA, Dawson AS. A 19-week exercise program for people with chronic stroke enhances bone geometry at the tibia: a peripheral quantitative computed tomography study. Osteoporos Int. 2006;17:1615-25.

**Table 1** Bone Parameters Measured and Their Precision Errors

| | Description | LSC (%) |
|---|---|---|
| **DXA parameters** | | |
| Ultradistal forearm aBMD (g/cm$^2$) | An area of predominately trabecular bone extending 15mm proximally from the cortical endplate of the radius. | 4.383 |
| Mid-forearm aBMD (g/cm$^2$) | The area between the ultradistal and one-third region. | 3.280 |
| 1/3 forearm aBMD (g/cm$^2$) | Centered 1/3 of the length of the forearm below the ulnar styloid. | 3.506 |
| Total forearm aBMD (g/cm$^2$) | The mean density of the mineral content within the area scanned. | 2.630 |
| **pQCT parameters (4% radius site)** | | |
| Total area (mm$^2$) | Cross sectional area of the bone after the soft tissue has been peeled off. | 8.540 |
| Total vBMD (mg/cm$^3$) | The mean density of the bone material within a 1mm slice. | 8.201 |
| Trabecular vBMD (mg/cm$^3$) | The mean density of the trabecular bone within a 1mm slice. | 4.977 |
| cBSI (mg$^2$/mm$^4$) | A bone strength index indicating the resistance against compressive forces. | 14.988 |
| **pQCT parameters (33% radius site)** | | |
| Total area (mm$^2$) | Cross sectional area of the bone after the soft tissue has been peeled off. | 5.571 |
| Cortical vBMD (mg/cm$^3$) | The mean density of the pure cortical bone within a 1mm slice. | 1.527 |
| Cortical BMC (mg/mm) | The mineral content of the pure cortical bone within a 1mm slice. | 1.951 |
| Cortical bone area (mm$^2$) | The area that is assigned to be pure cortical. | 2.856 |
| Marrow cavity area (mm$^2$) | The cortical area subtracted from the total area. | 17.957 |
| Cortical thickness (mm) | The difference between the outer and the inner radius of the cortical shell. | 5.797 |
| p-SSI (mm$^3$) | A bone strength index indicating the resistance against torsional loads. | 6.674 |

CV = coefficient of variation, DXA = dual-energy X-ray absorptiometry, aBMD= areal bone mineral density, vBMD = volumetric bone mineral density, cBSI = compressive bone strength index, pQCT = peripheral quantitative computed tomography, BMC = bone mineral content, p-SSI = polar stress-strain index, LSC = least significant change

**Table 2** Changes in Areal Bone Mineral Density (aBMD) in the Forearm

| | Paretic side | | | Non-paretic side | | |
|---|---|---|---|---|---|---|
| **Parameter** | **Initial** | **Follow-up** | **% change[#]** | **Initial** | **Follow-up** | **% change[#]** |
| Ultradistal forearm aBMD ($g/cm^2$) | 0.453 | 0.417 | -7.9* | 0.455 | 0.459 | 0.9 |
| Mid-forearm aBMD ($g/cm^2$) | 0.705 | 0.670 | -5.0* | 0.691 | 0.719 | 4.0* |
| 1/3 forearm aBMD ($g/cm^2$) | 0.837 | 0.821 | -1.9 | 0.847 | 0.867 | 2.4 |
| Total forearm aBMD ($g/cm^2$) | 0.669 | 0.636 | -4.8* | 0.665 | 0.683 | 2.8* |

[#] A negative % change denotes a lower value on the follow-up assessment than the initial assessment.

*Change exceeds the least significant change value.

**Table 3** Changes in Volumetric Bone Mineral Density (vBMD) and Geometry in the Radius Epiphysis and Diaphysis

| | Paretic side | | | Non-paretic side | | |
|---|---|---|---|---|---|---|
| | **Initial** | **Follow-up** | **% change#** | **Initial** | **Follow-up** | **% change#** |
| **Radius epiphysis (4% site)** | | | | | | |
| Total area ($mm^2$) | 280.0 | 288.8 | 3.1 | 261.0 | 267.0 | 2.2 |
| Total vBMD ($mg/cm^3$) | 474.1 | 416.6 | -12.1* | 505.1 | 493.1 | -2.4 |
| Trabecular vBMD ($mg/cm^3$) | 238.3 | 229.5 | -3.7 | 243.8 | 245.3 | 0.6 |
| cBSI ($mg^2/mm^4$) | 62.9 | 50.1 | -20.6* | 66.6 | 64.9 | -2.5 |
| **Radius diaphysis (33% site)** | | | | | | |
| Total area ($mm^2$) | 141.3 | 143.8 | 1.8 | 143.5 | 141.3 | -1.5 |
| Cortical vBMD ($mg/cm^3$) | 1218.8 | 1222.9 | 0.3 | 1214.0 | 1232.0 | 1.5 |
| Cortical BMC (mg/mm) | 122.5 | 120.8 | -1.4 | 122.4 | 124.8 | 2.0* |
| Cortical bone area ($mm^2$) | 100.5 | 98.8 | -1.7 | 100.8 | 101.3 | 0.5 |
| Marrow cavity area ($mm^2$) | 40.8 | 45.0 | 10.3 | 42.7 | 40.0 | -6.4 |
| Cortical thickness (mm) | 3.1 | 3.0 | -3.2 | 3.1 | 3.1 | 0.0 |
| p-SSI ($mm^3$) | 368.1 | 367.9 | 0.0 | 352.0 | 378.9 | 7.6* |

BMC = bone mineral content, cBSI = compressive bone strength index, p-SSI = polar stress-strain index, vBMD = volumetric bone mineral density

# A negative % change denotes a lower value on the follow-up assessment than the initial assessment.

*Change exceeds the least significant change (LSC) value

**Figure 1** Changes in Grip Strength, Motor Function, Disuse, and Spasticity of the Paretic Upper Extremity During the Follow-Up Period

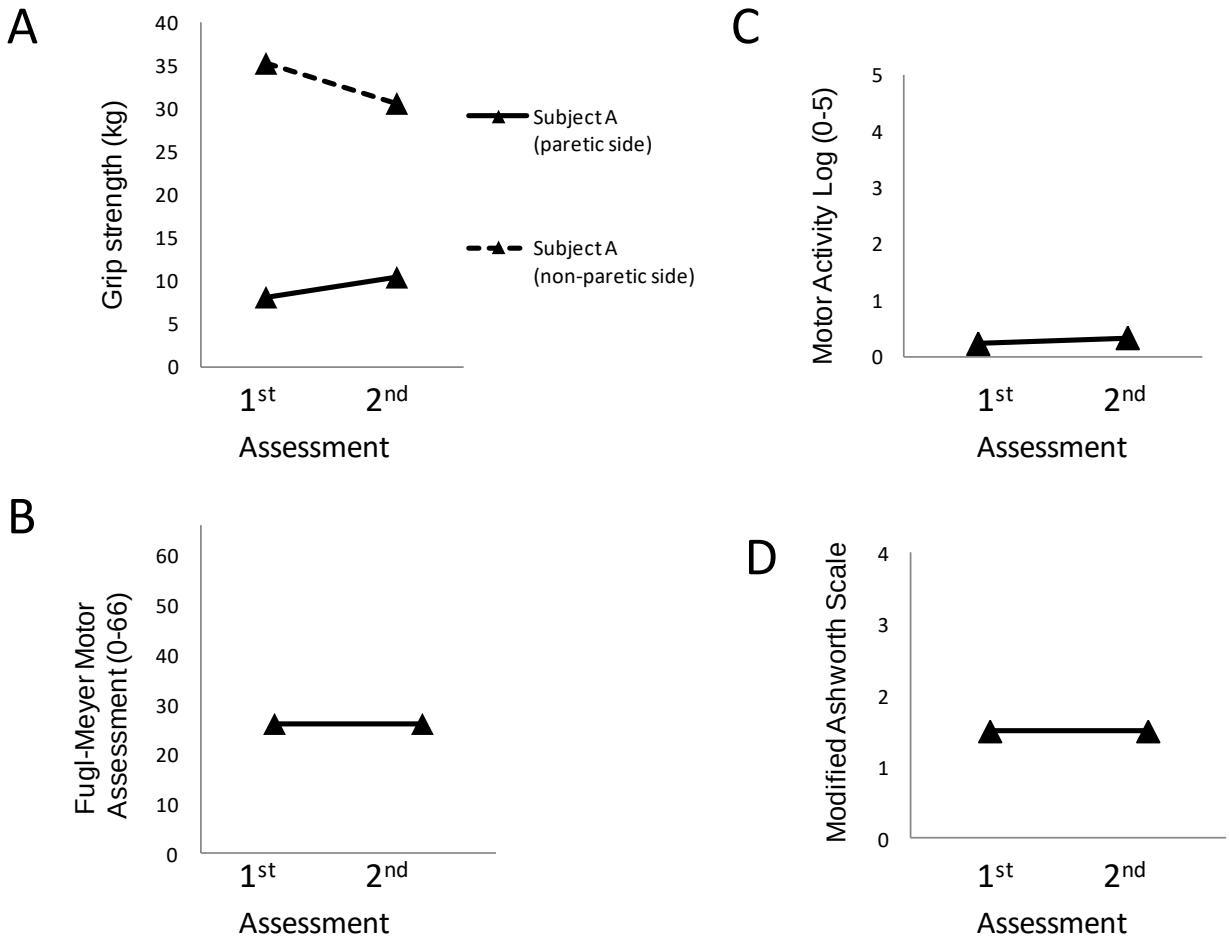

**FIGURE LEGEND**

**Figure 1** Changes in grip strength, motor function, disuse, and spasticity of the paretic upper extremity during the follow-up period

The data on (A) grip strength, (B) Fugl-Meyer Motor Assessment score, (C) Motor Activity Log score and (D) Modified Ashworth Scale score are shown. The subject demonstrated no substantial change in these variables during the follow-up period.